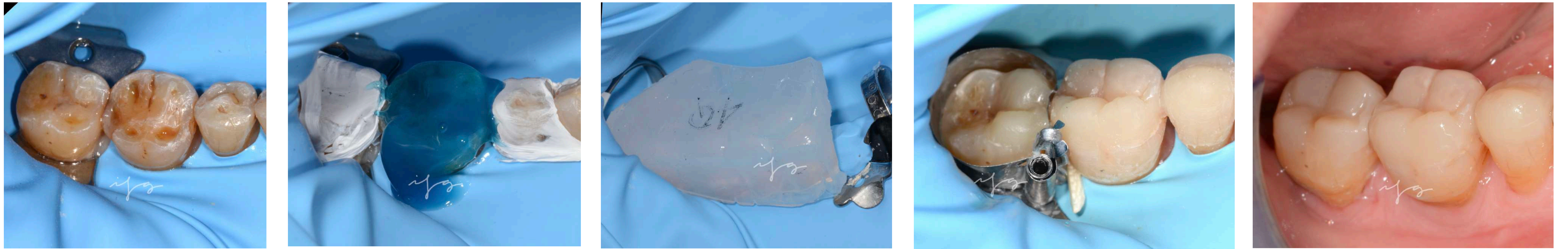


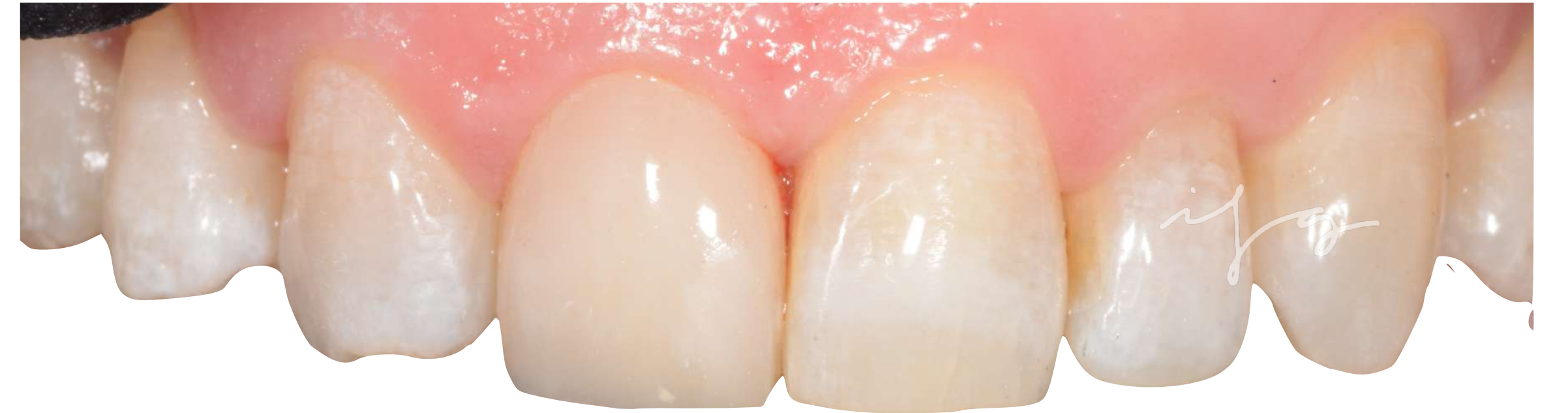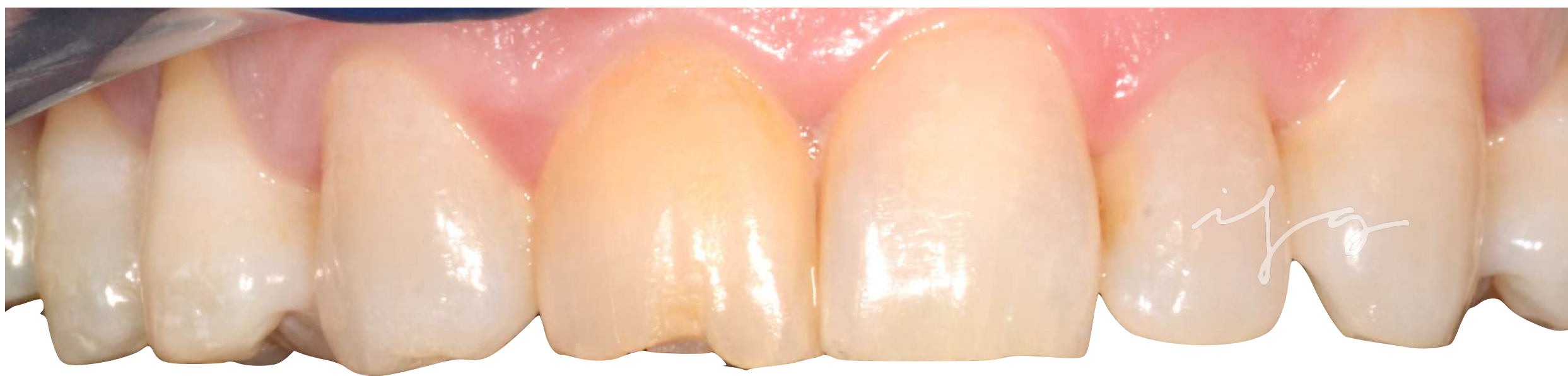INÉS FERNÁNDEZ GUALLART

~ A sample of my work ~

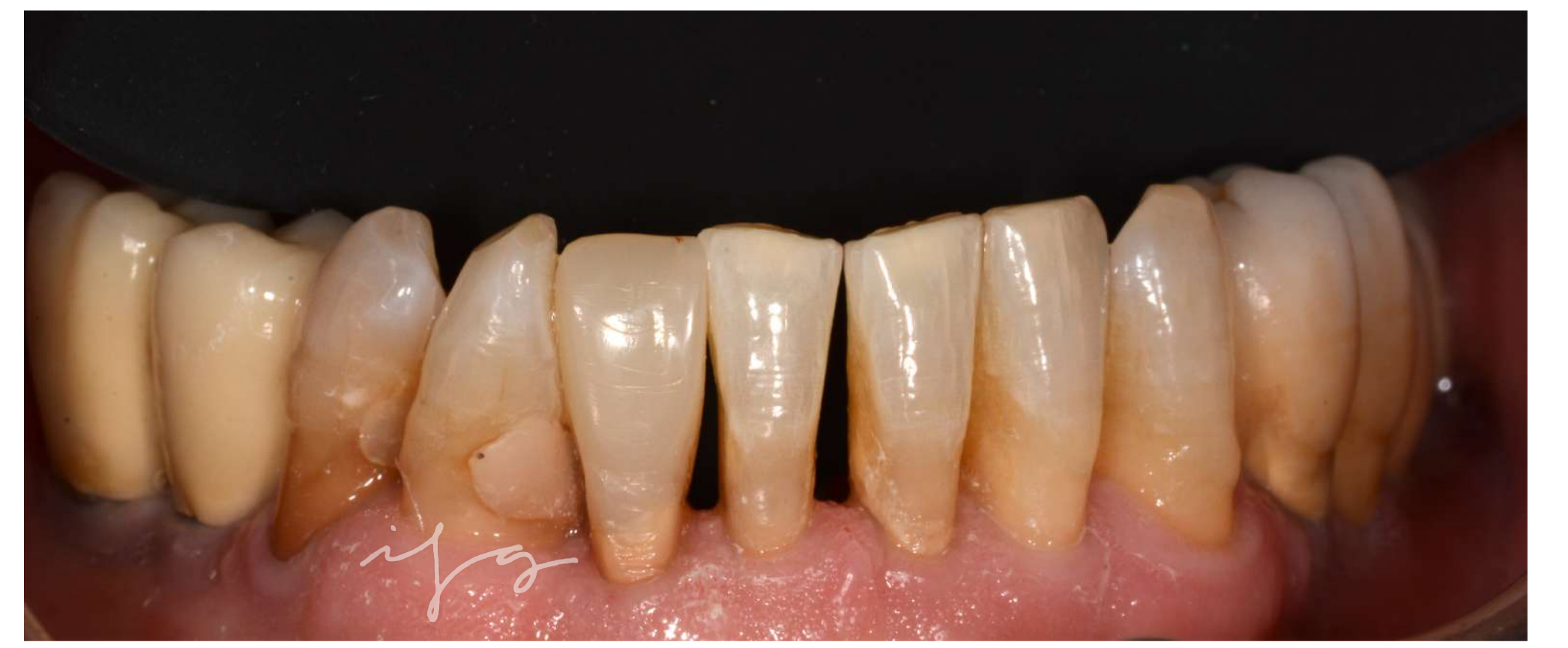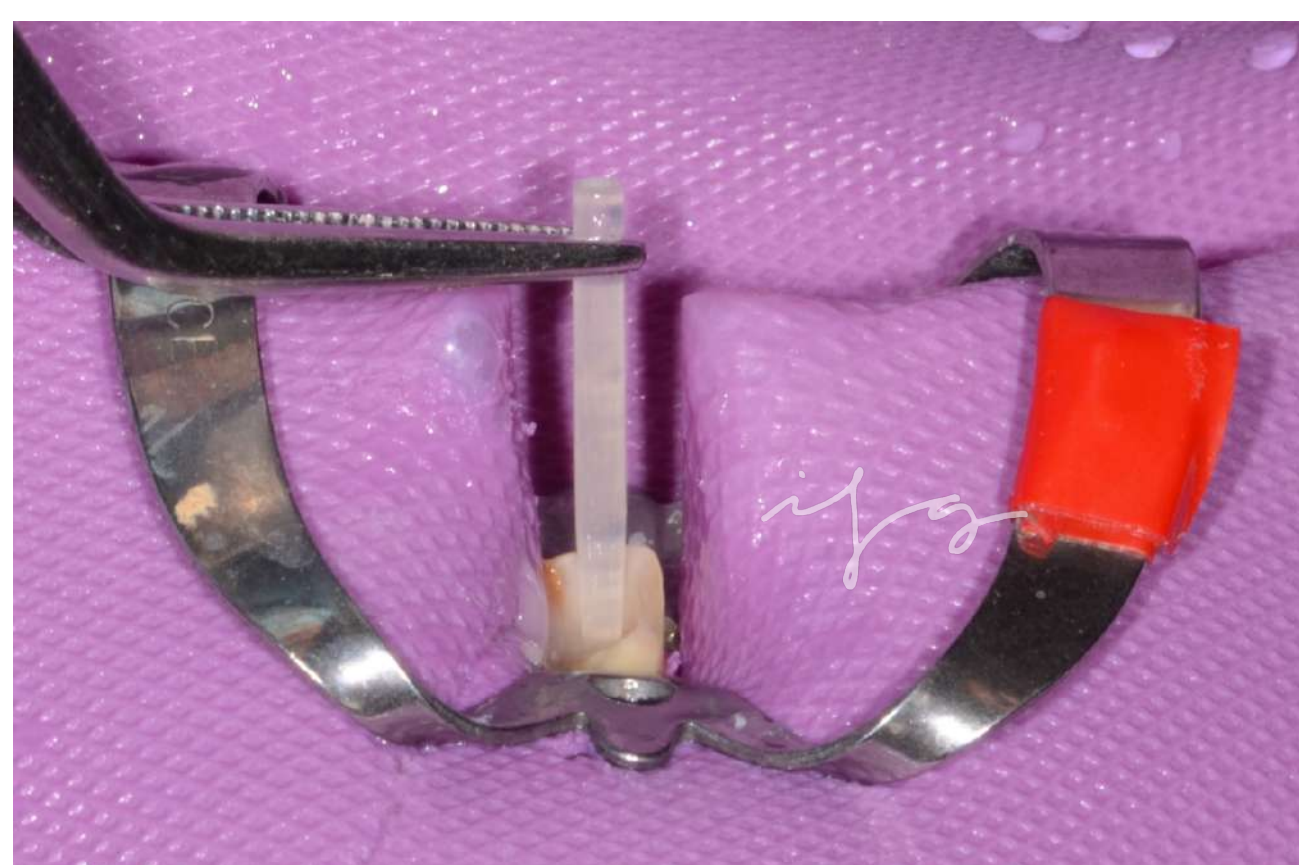
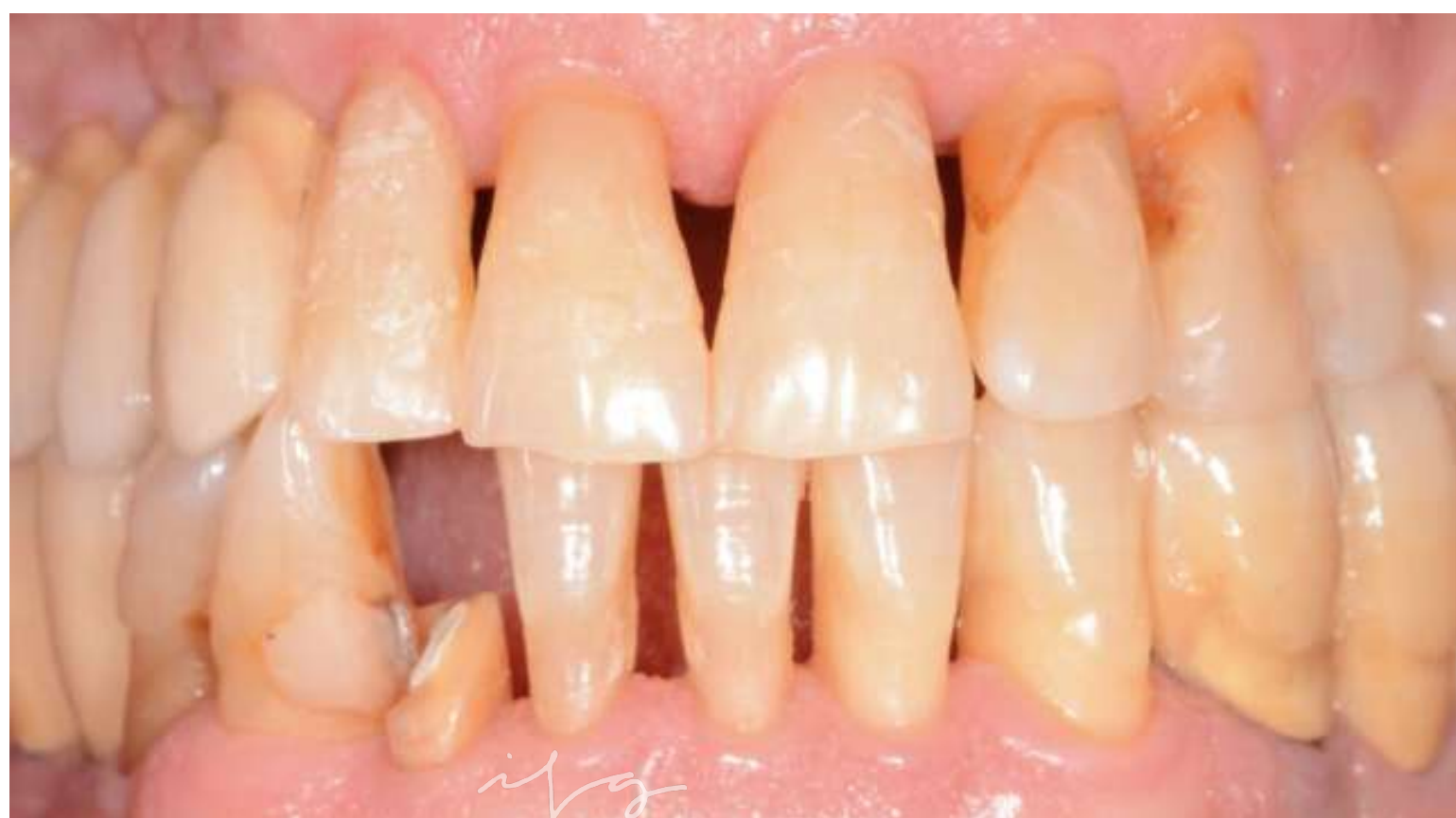Minimally invasive dentistry - chairside composites



Posterior chairside composites to raise VDO

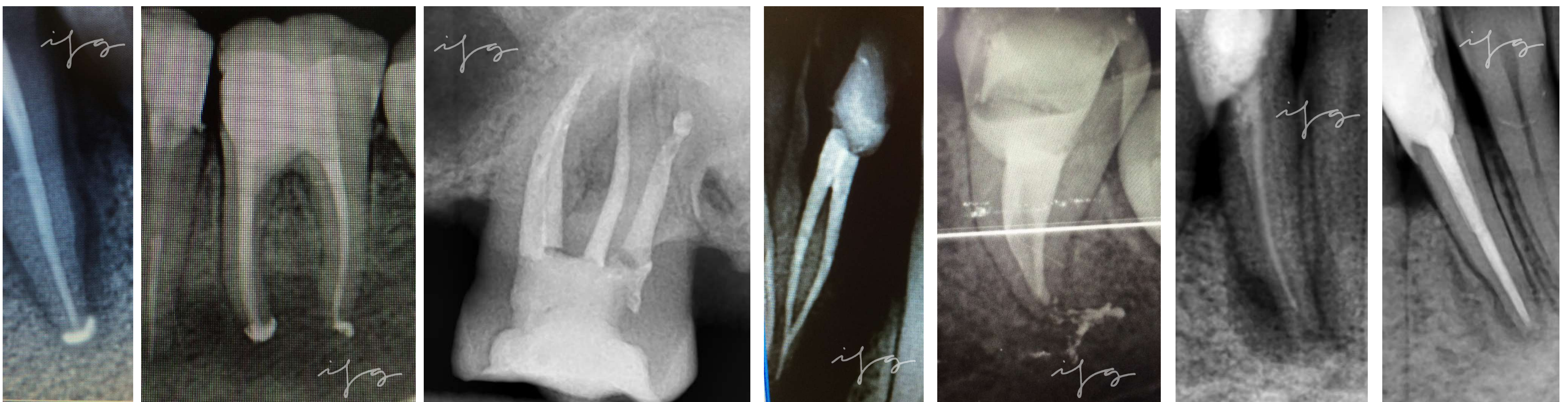


Single composite veneer restoration in #1.1



Composite restoration in #4.2 with fiber post

Endodontics

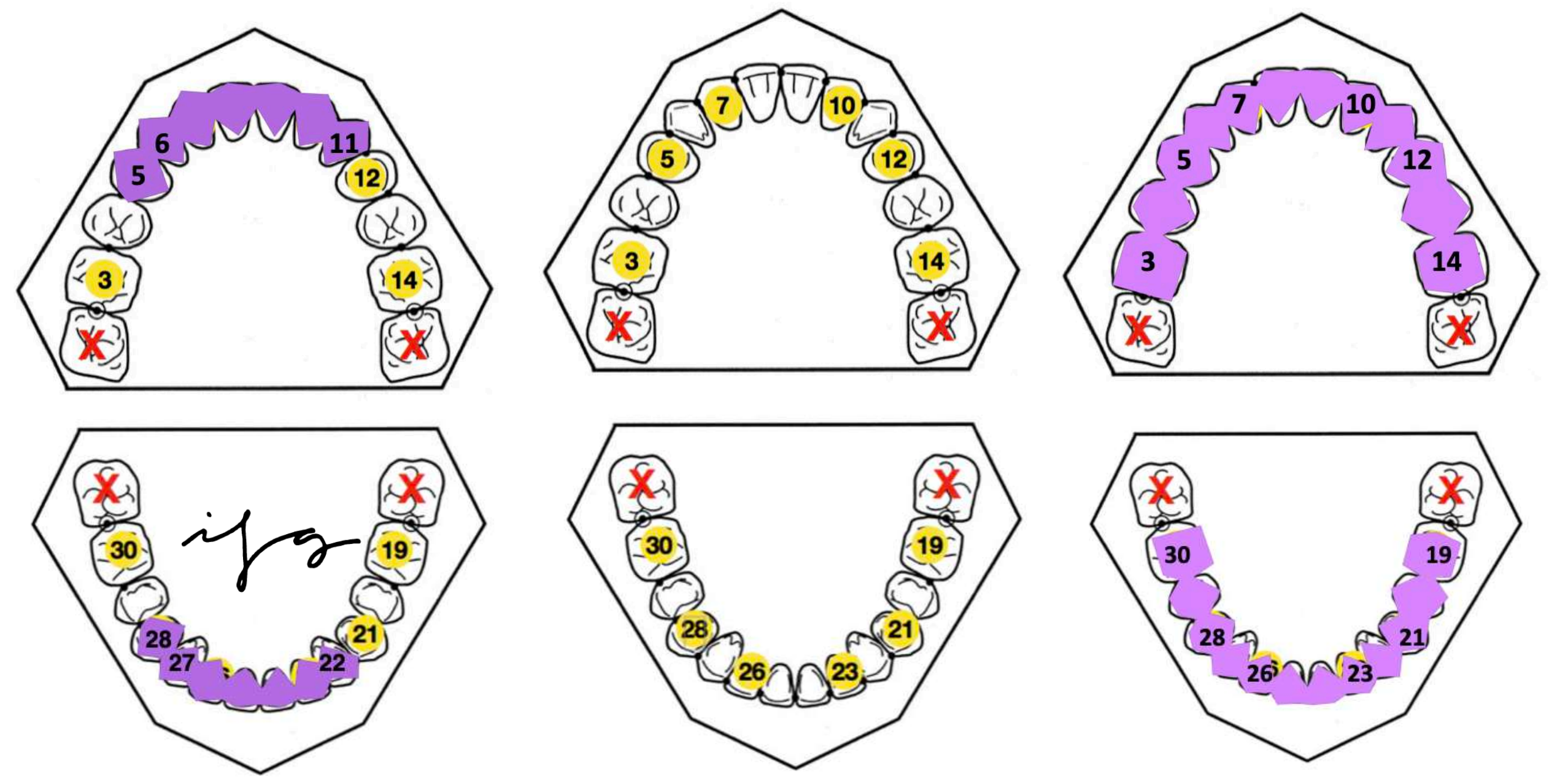
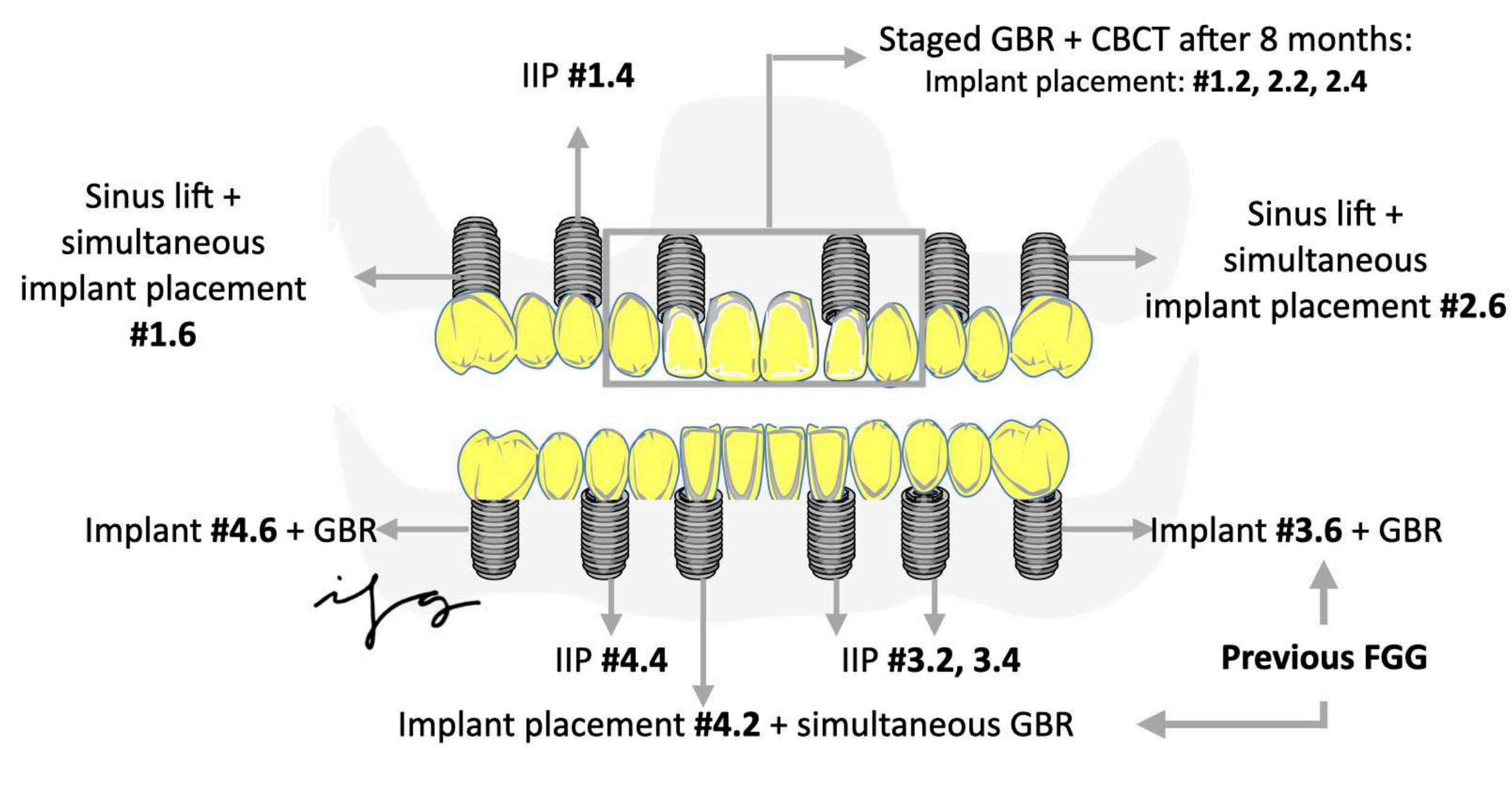


Root canal treatment of single and multiple canals

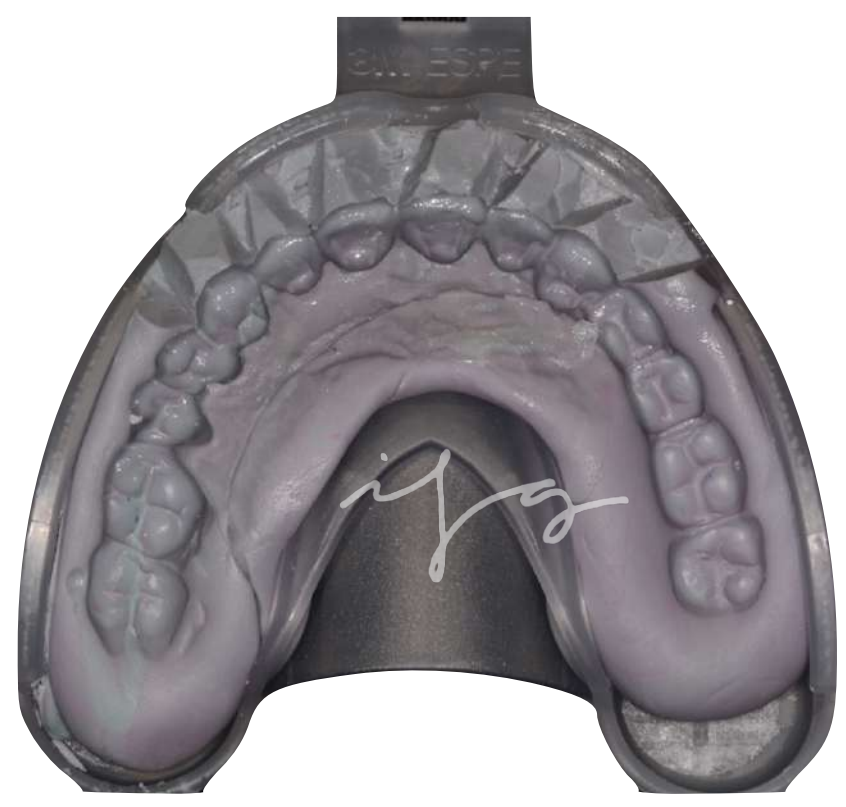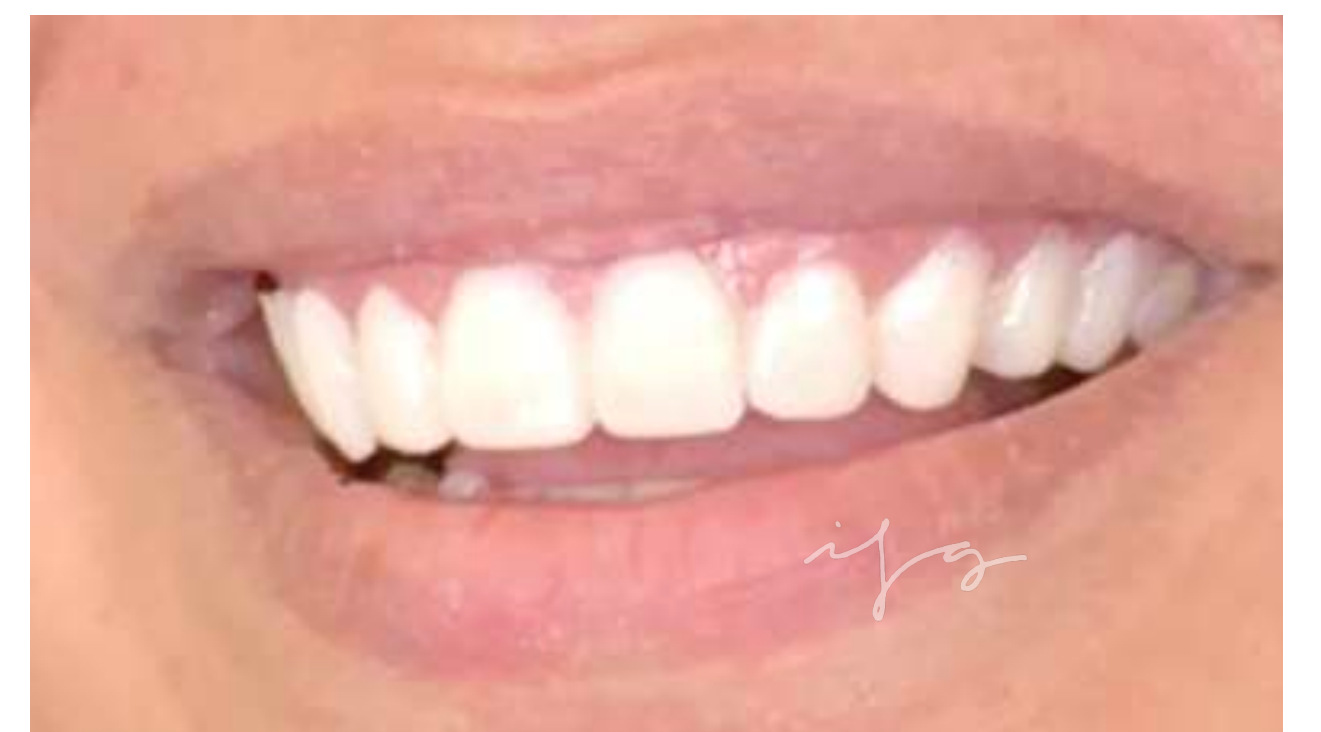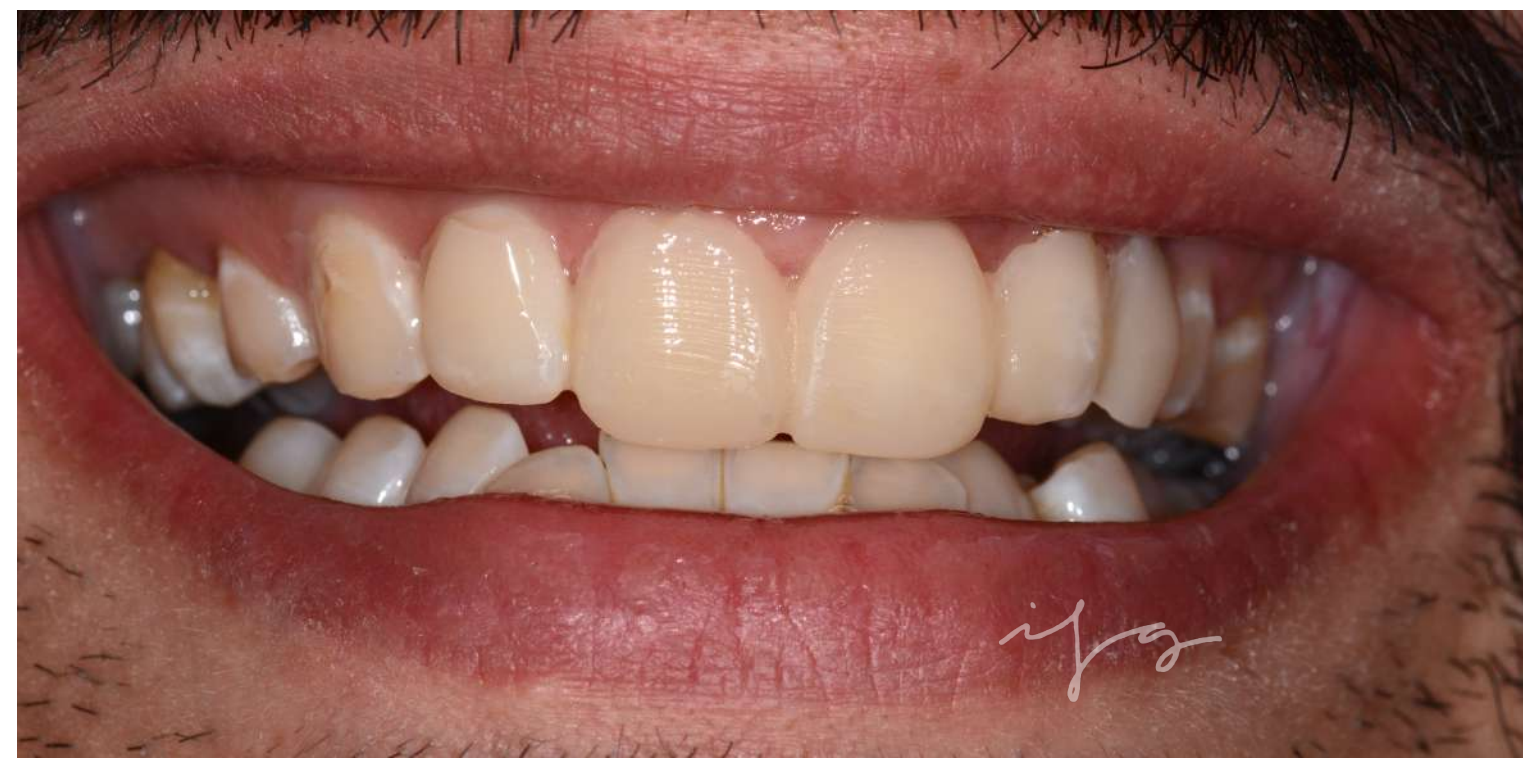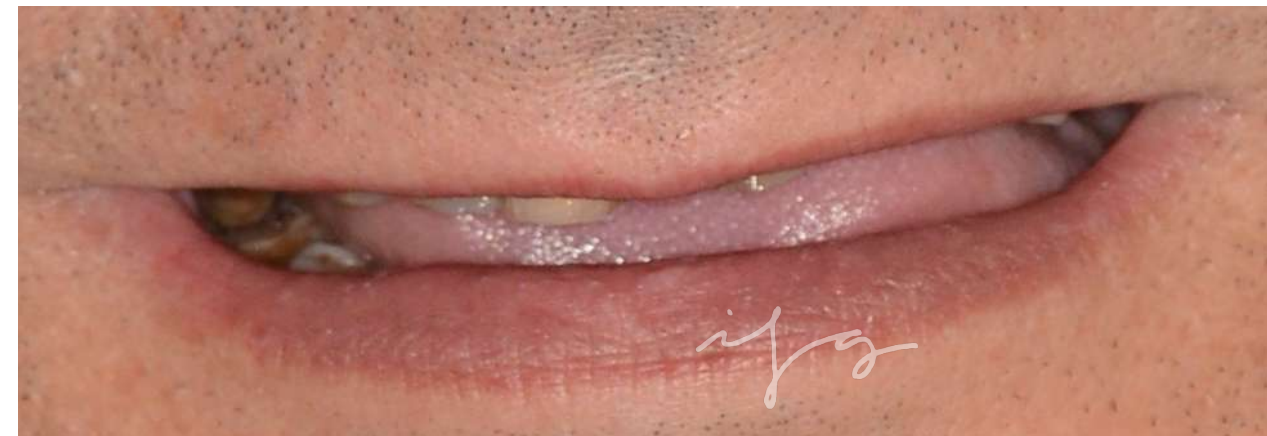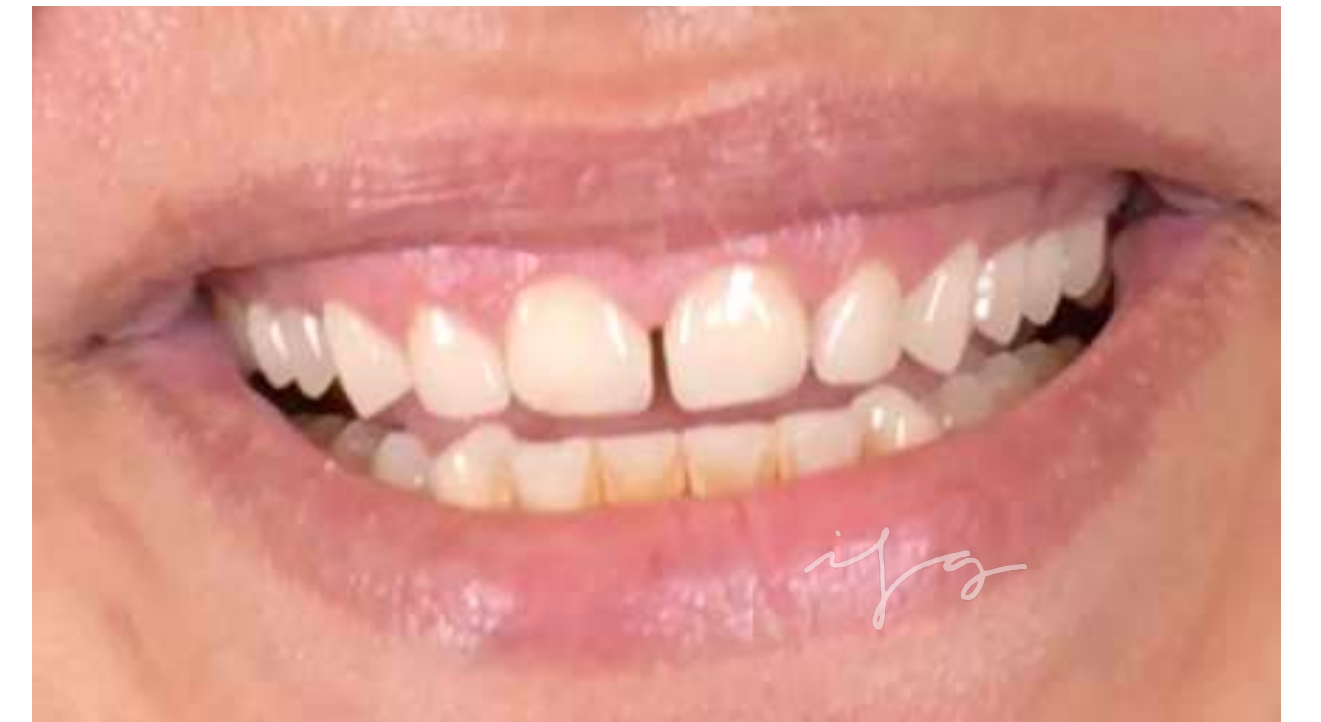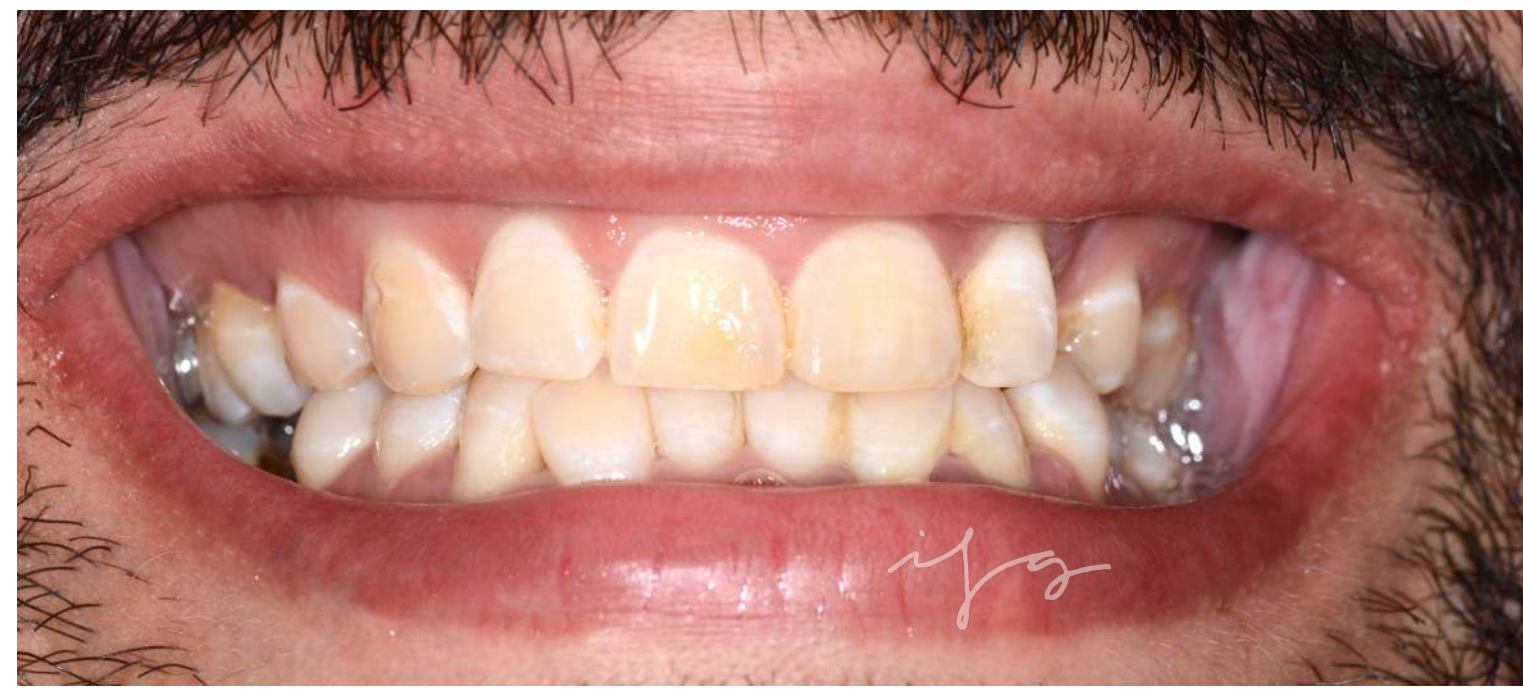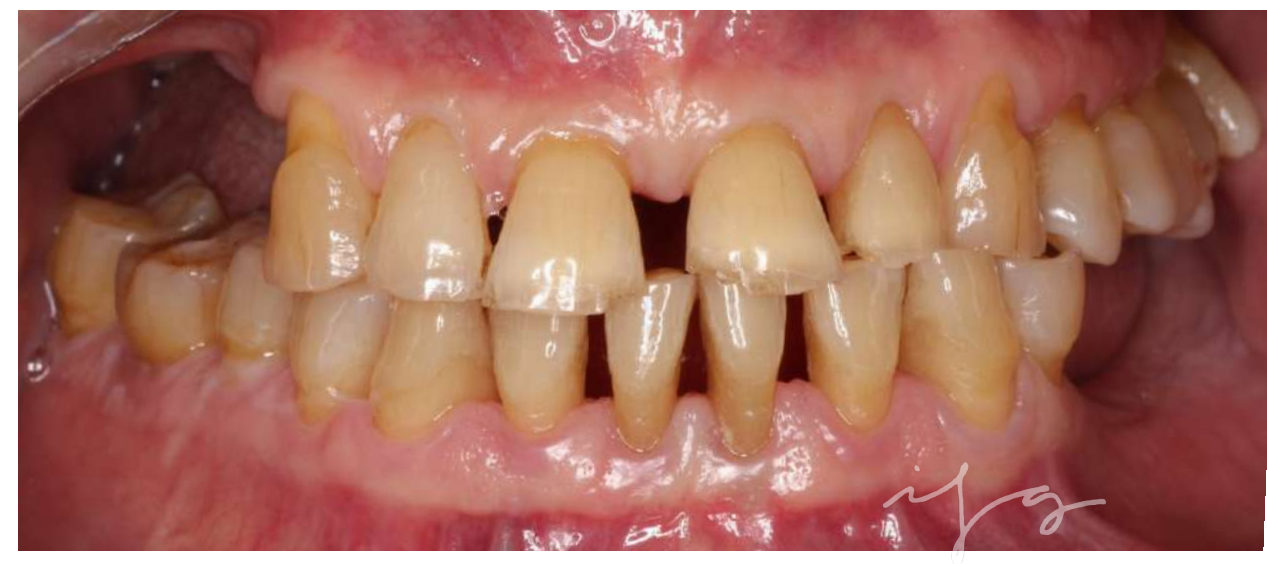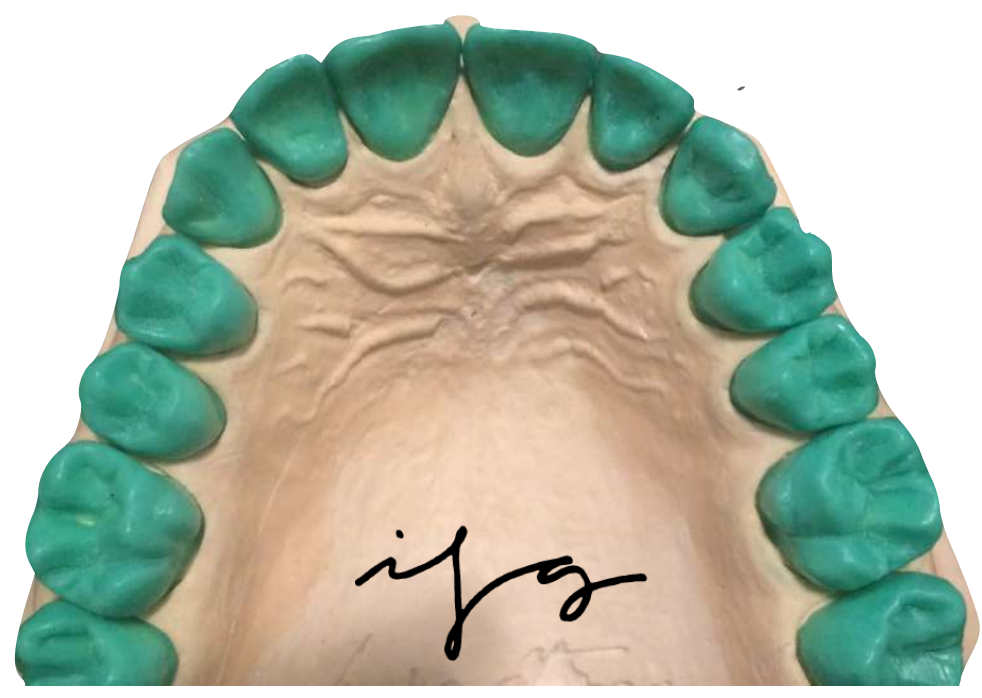Anatomical variations

Re-treatment

Full-mouth diagnosis / Wax-up and mock-up



Staged approach treatment planning for a full mouth implant-supported fixed restoration

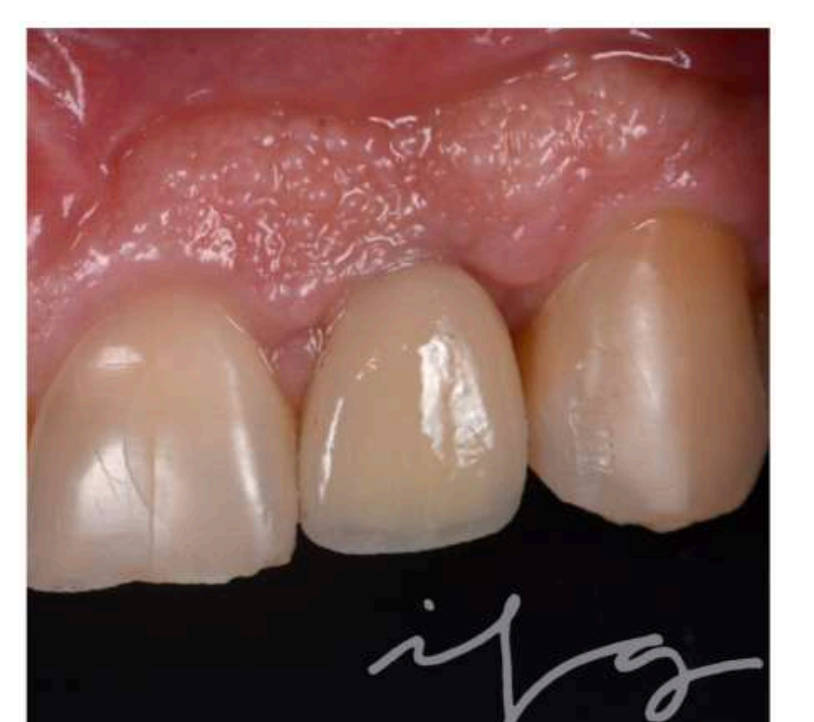
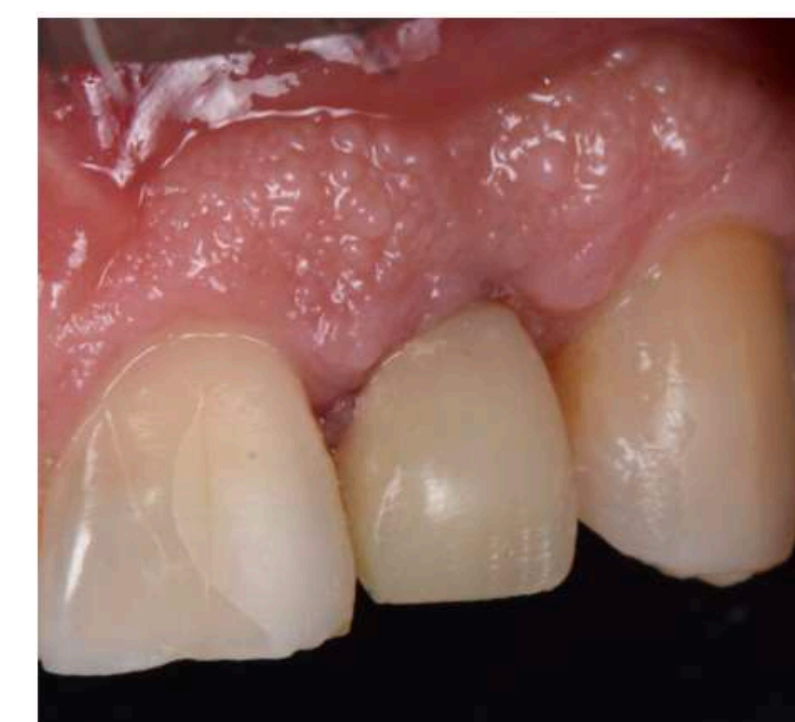
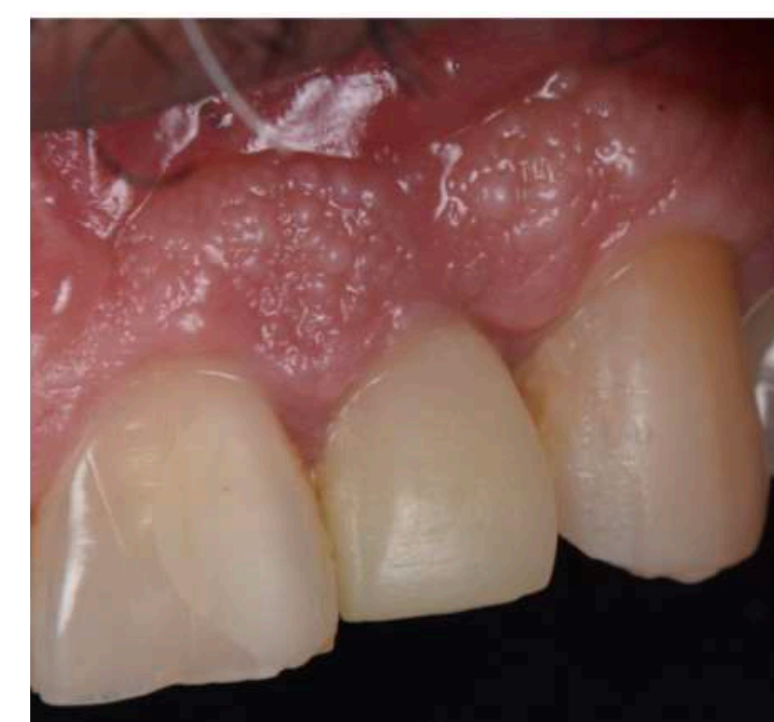
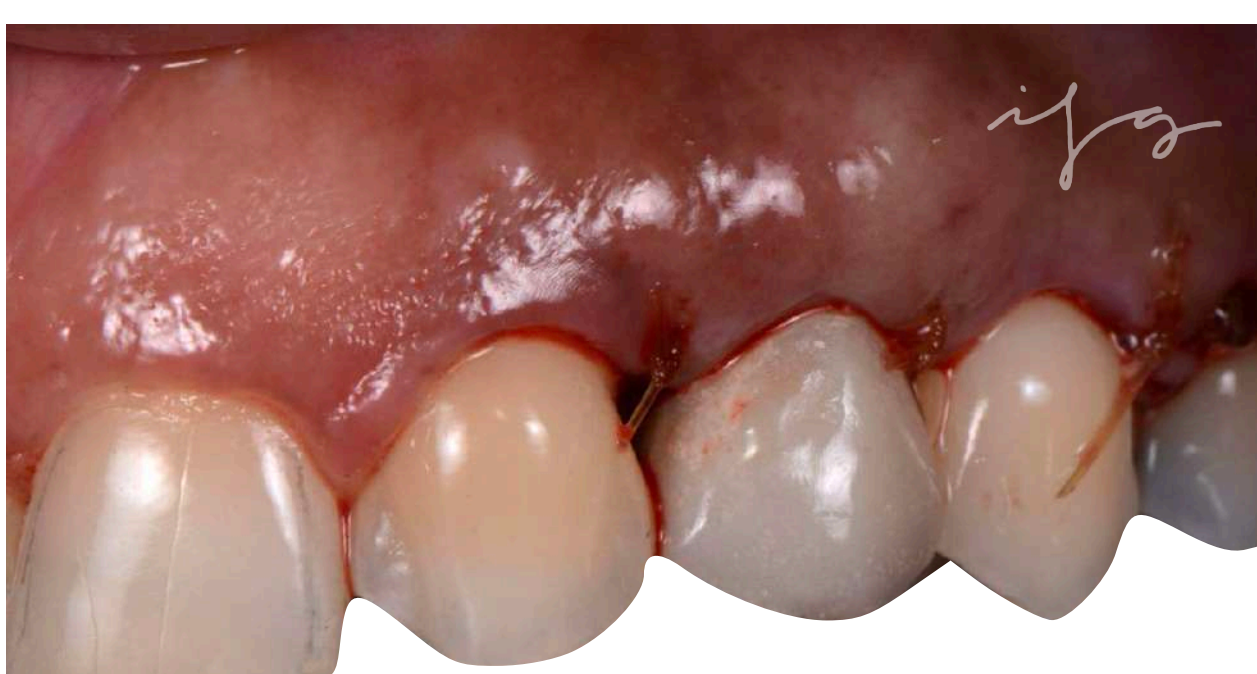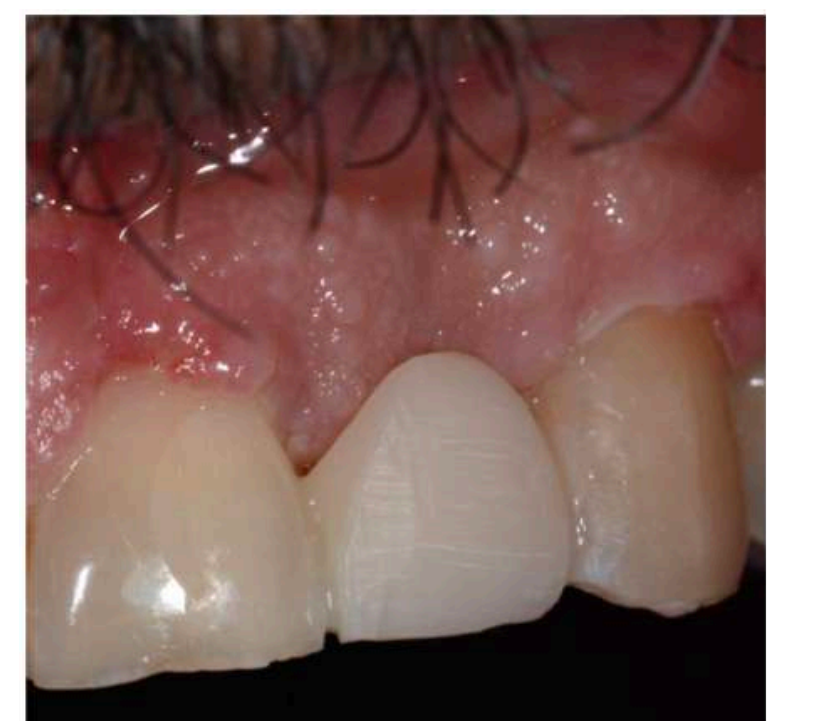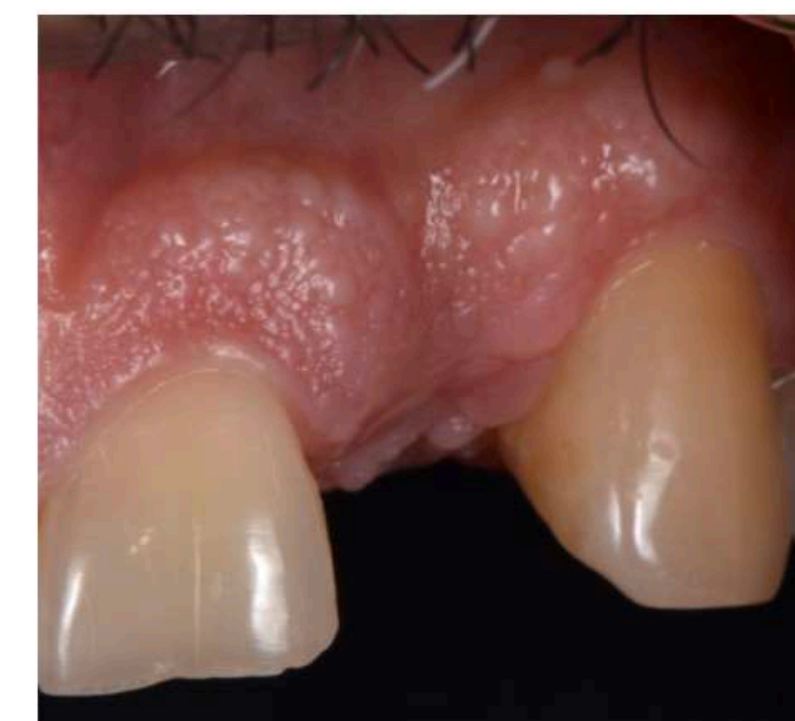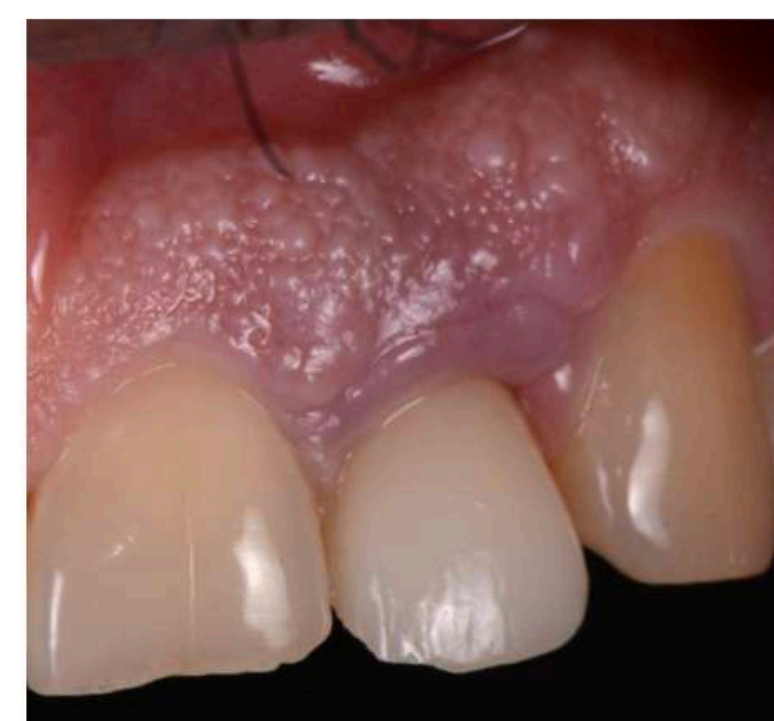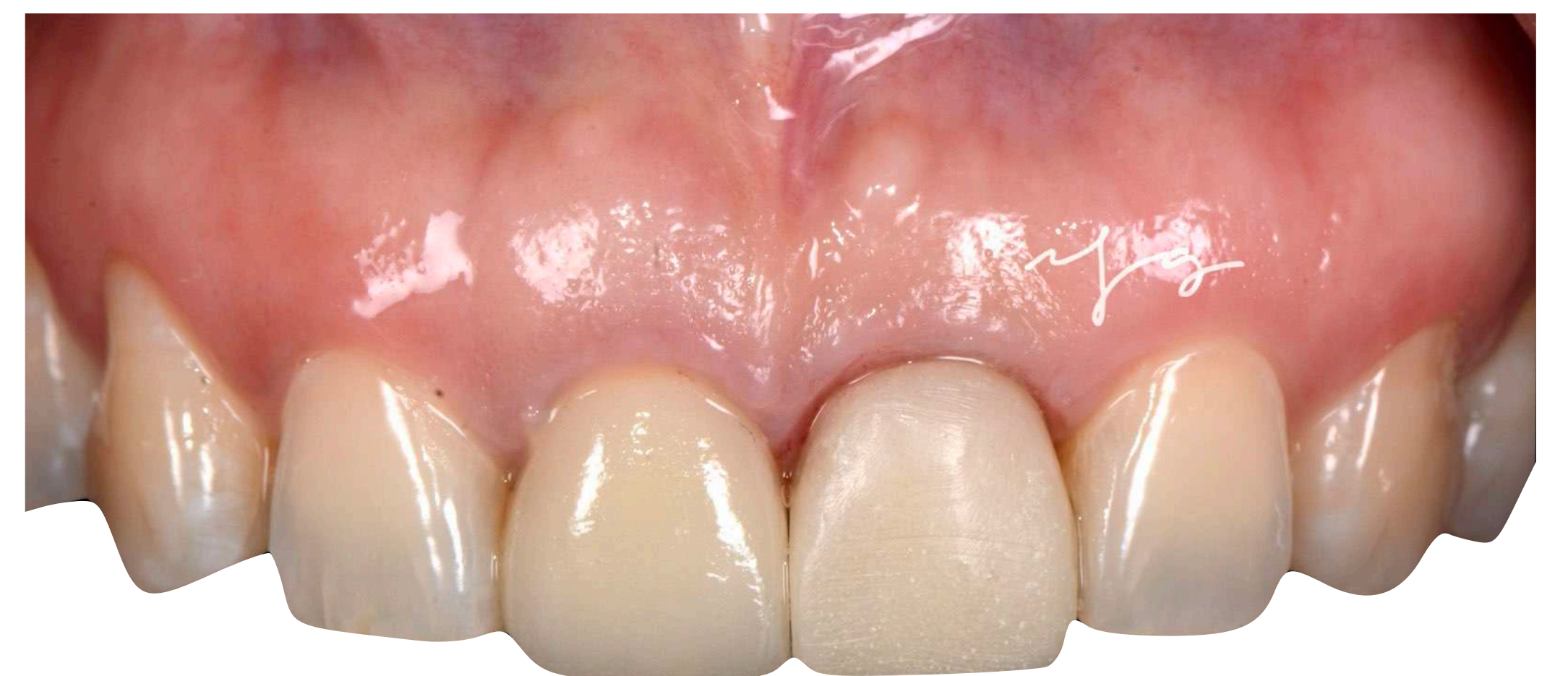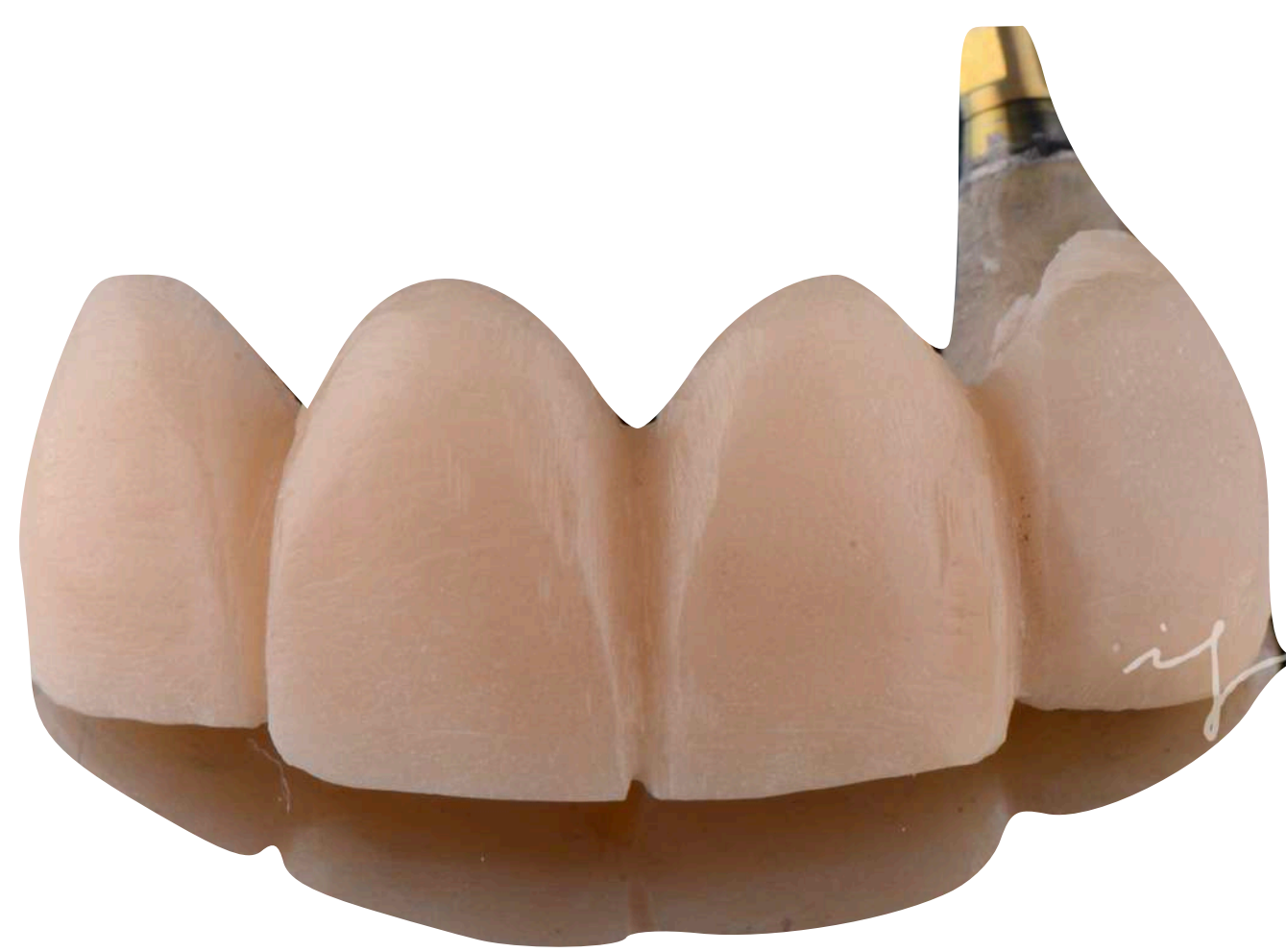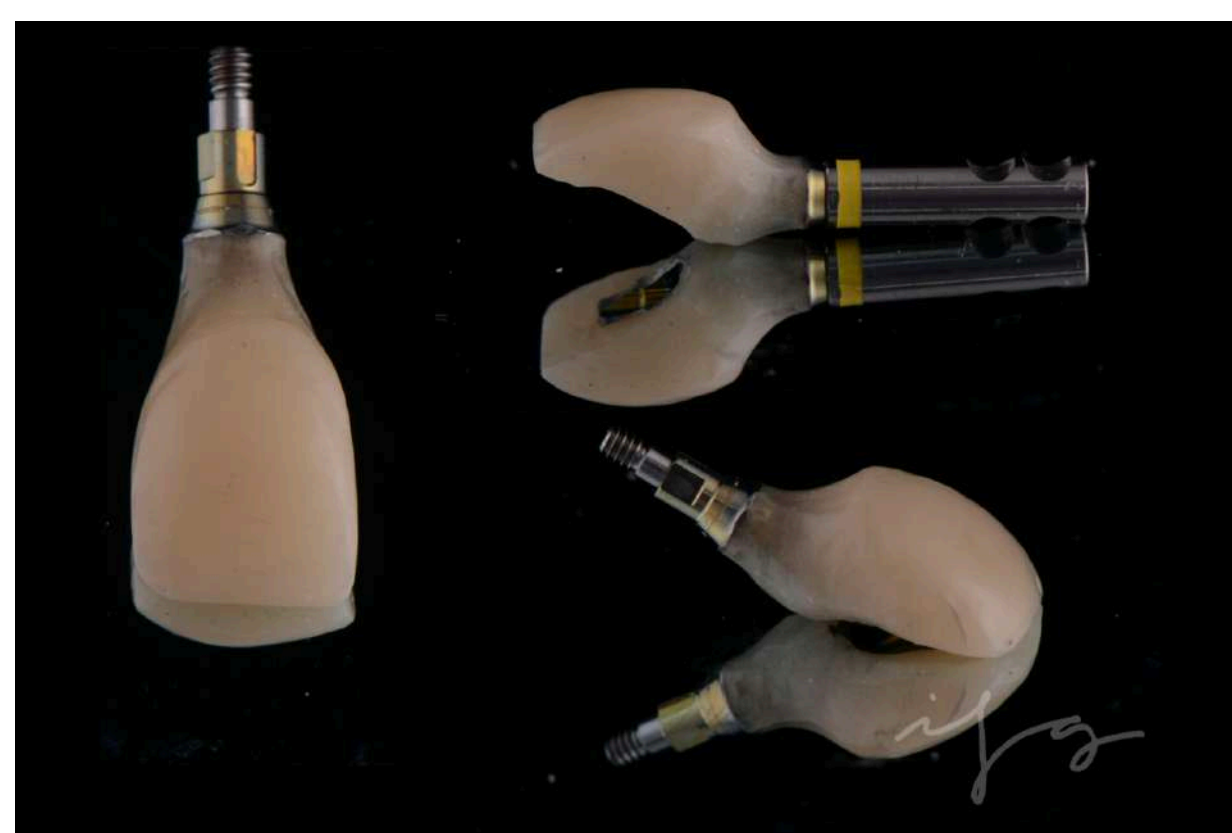Full-arch wax-up + Putty index

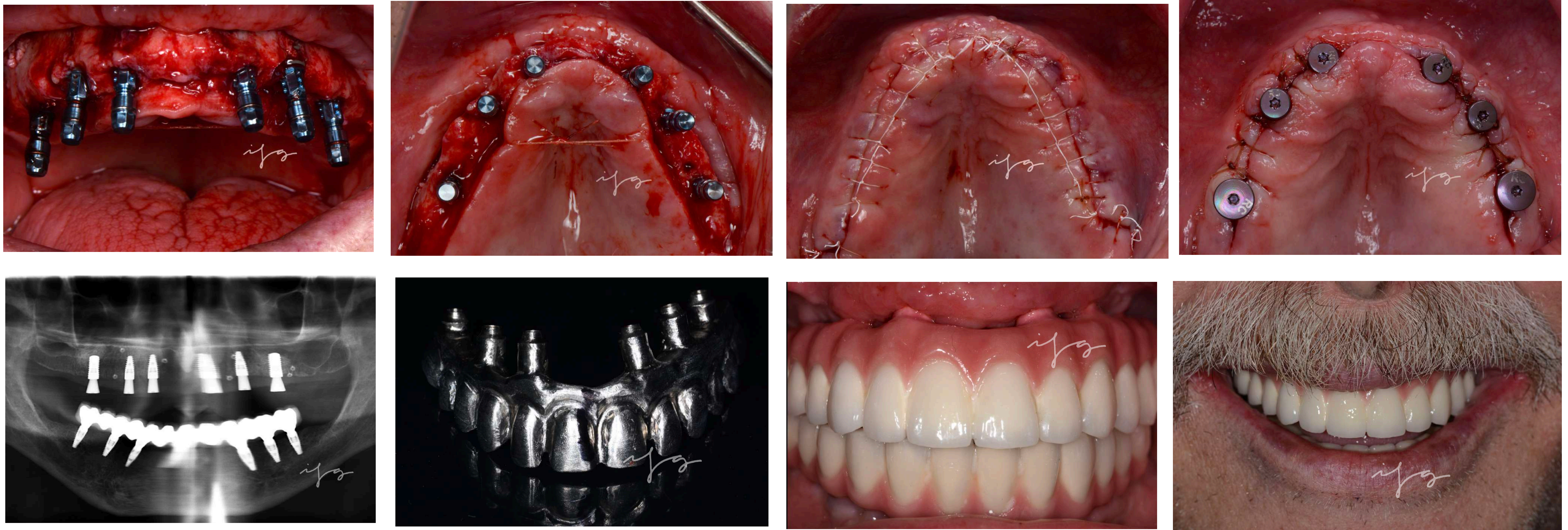
Mock-up for a full mouth VDO restoration

Mock-up for aesthetic crown lengthening

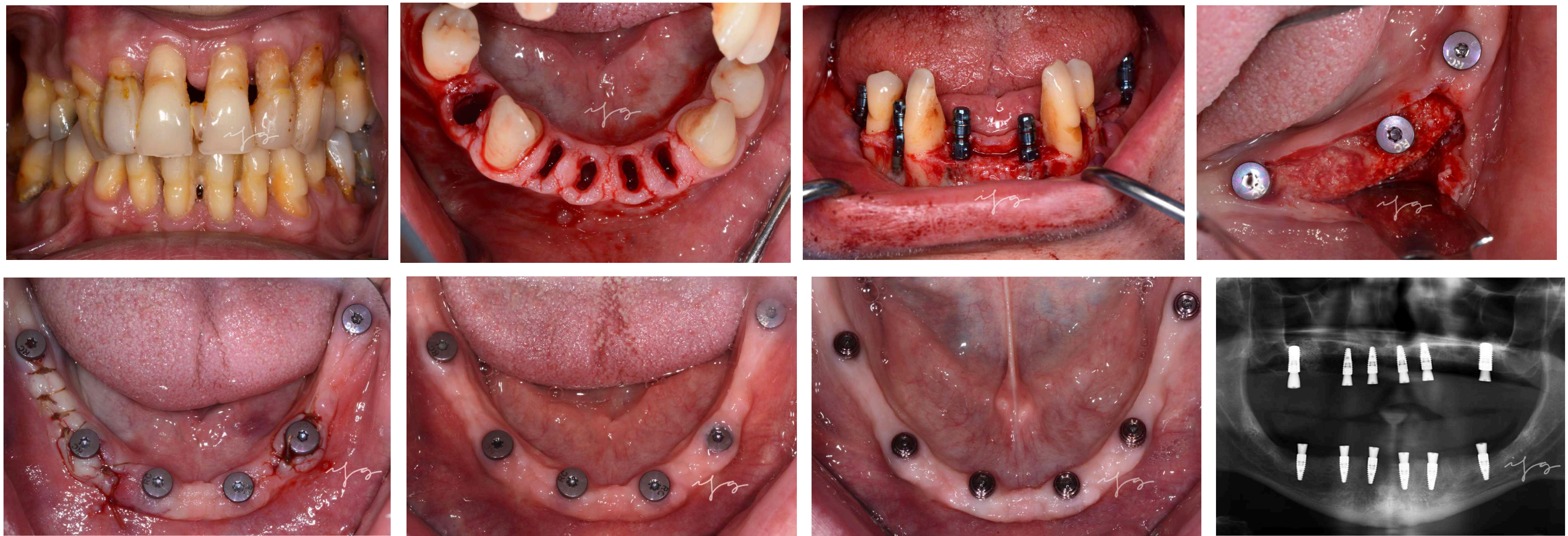
Chairside temporary fabrication - soft tissue development



Full-mouth implant treatment - surgical and restorative

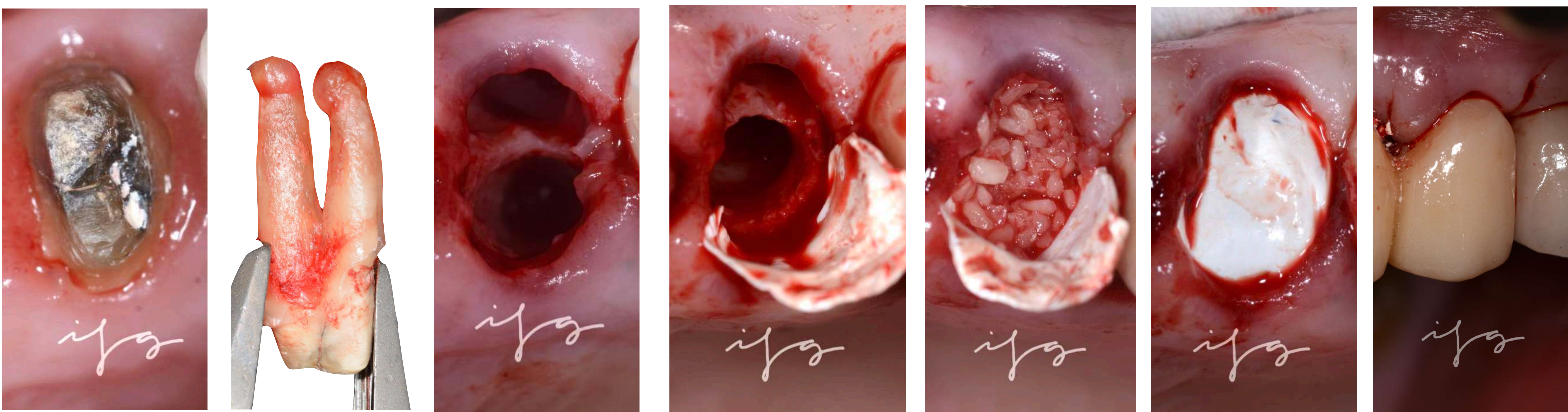


Full - mouth PFM rehabilitation: Maxillary treatment on six implants with bilateral sinus lift and GBR. One stage surgery



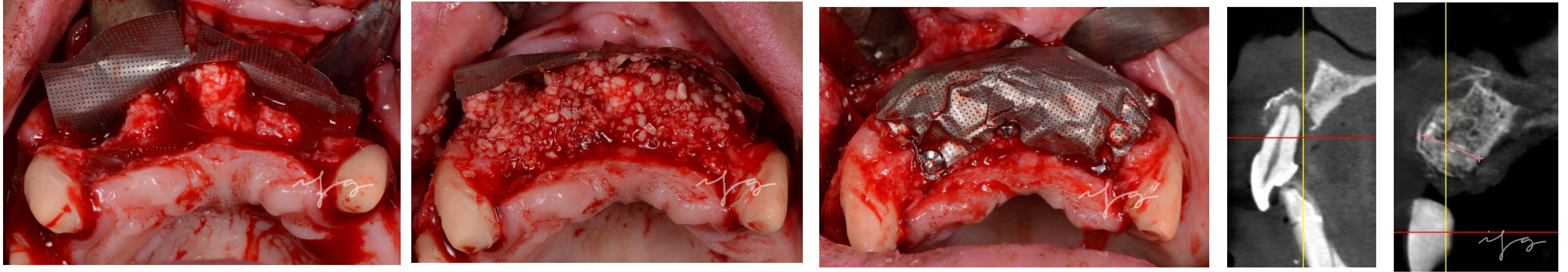
Full - mouth OD rehabilitation: Mandibular treatment on six implants with GBR. Serial extractions staged approach

Socket preservation

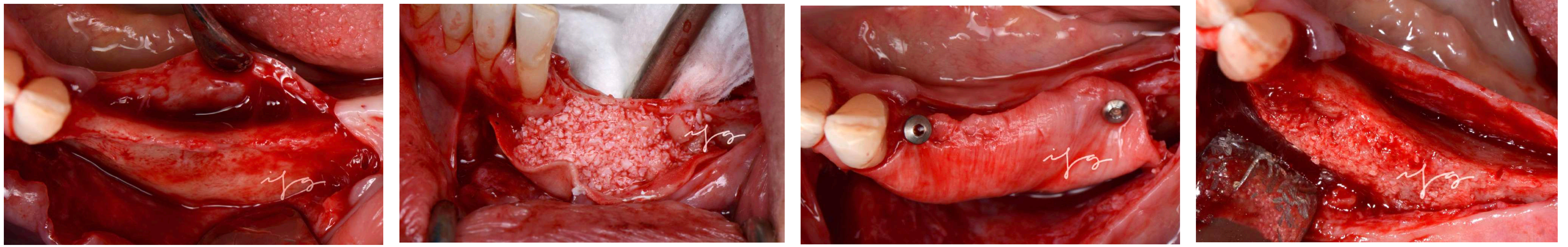


Socket preservation of 2.4 due to vertical fracture. Use of allograft and non-resorbable membrane

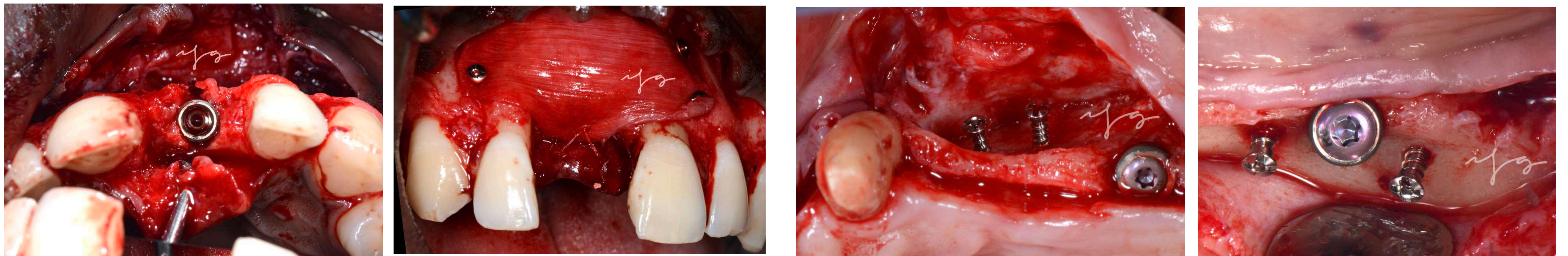
Guided bone regeneration (GBR)



Staged anterior maxilla GBR with non - resorbable membrane: Ti-foil + autologous + xenograft. 9 months

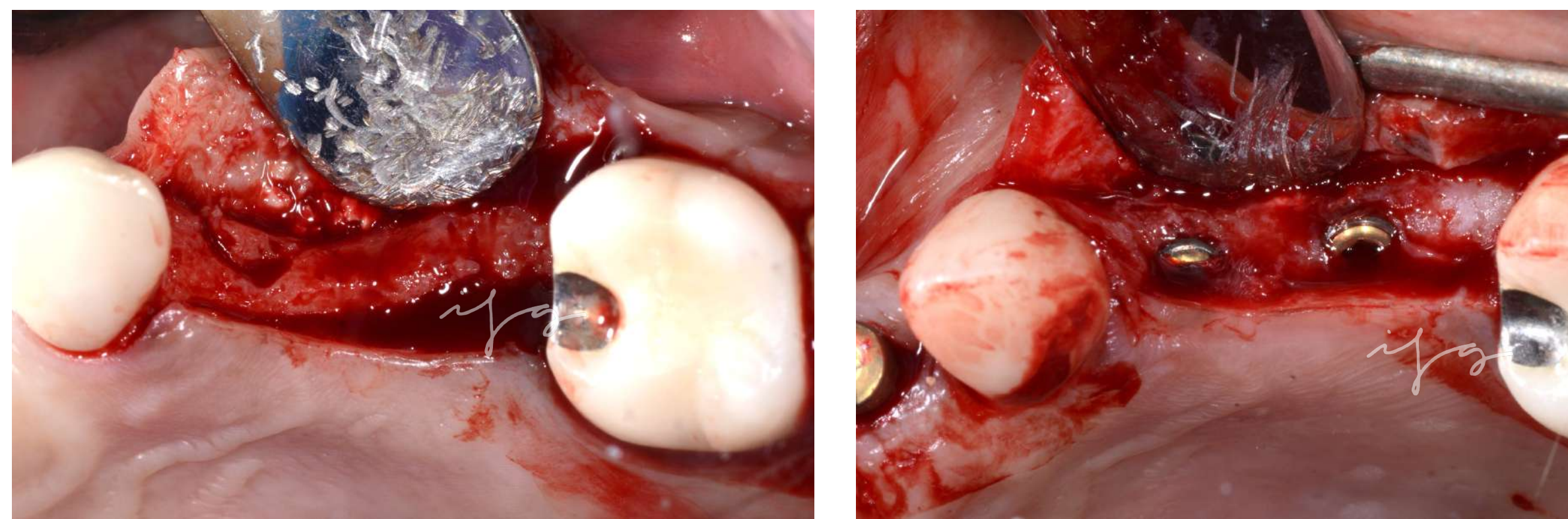


Staged posterior mandible GBR with resorbable membrane: autologous + xenograft. 4 months

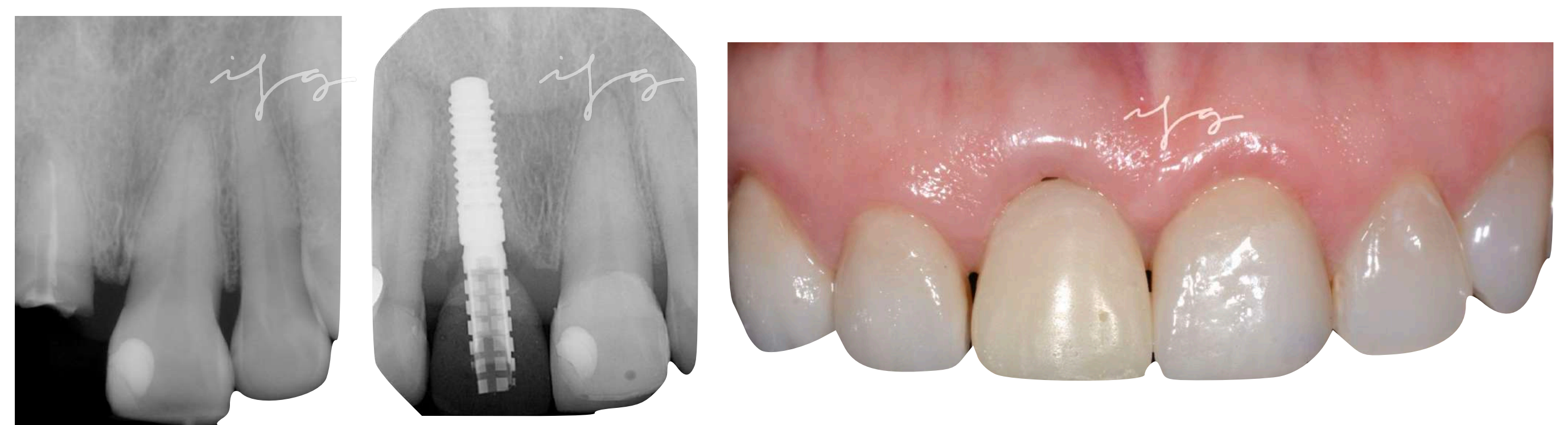

Simultaneous anterior GBR

GBR with use of tenting screws

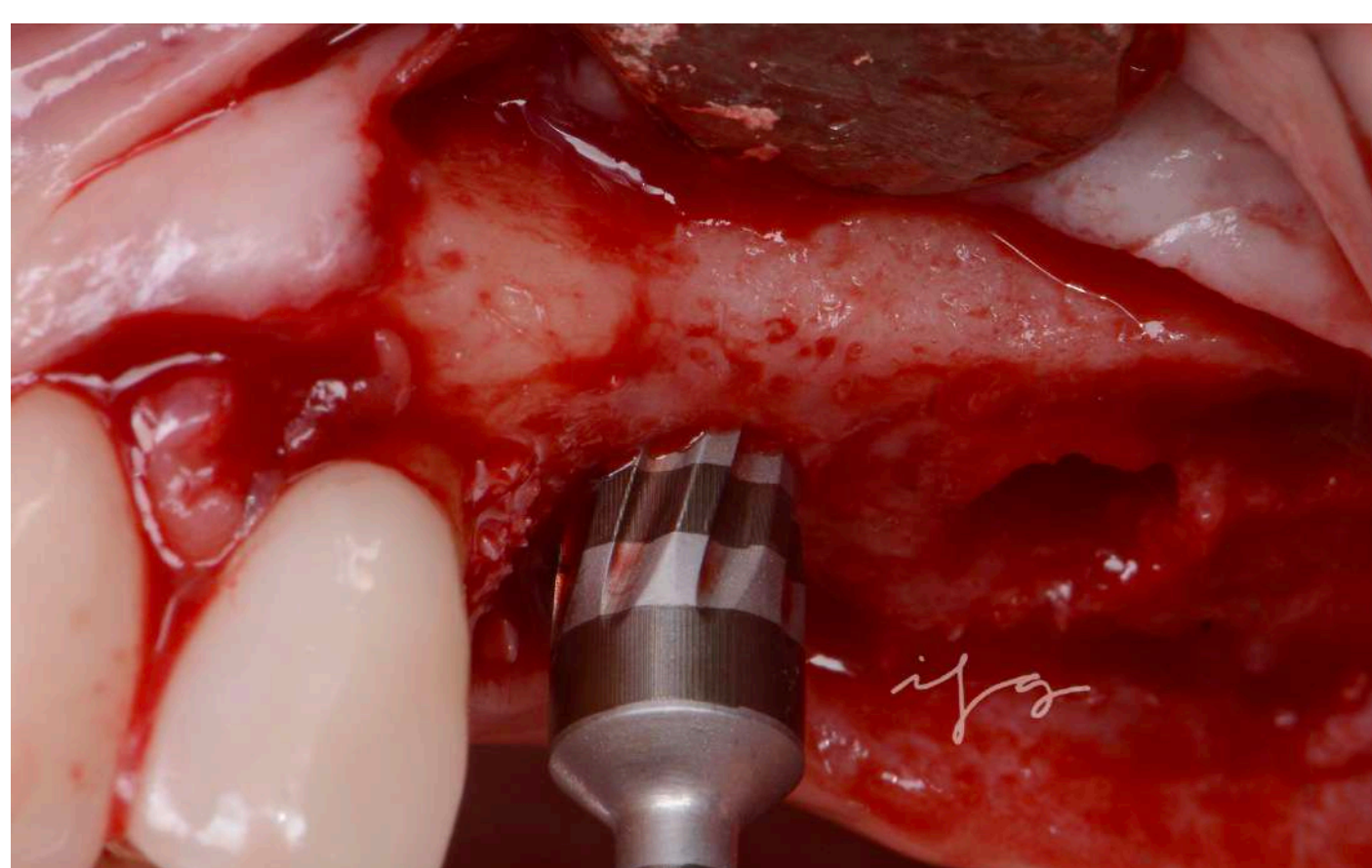


CARS : Customized Alveolar Ridge Split

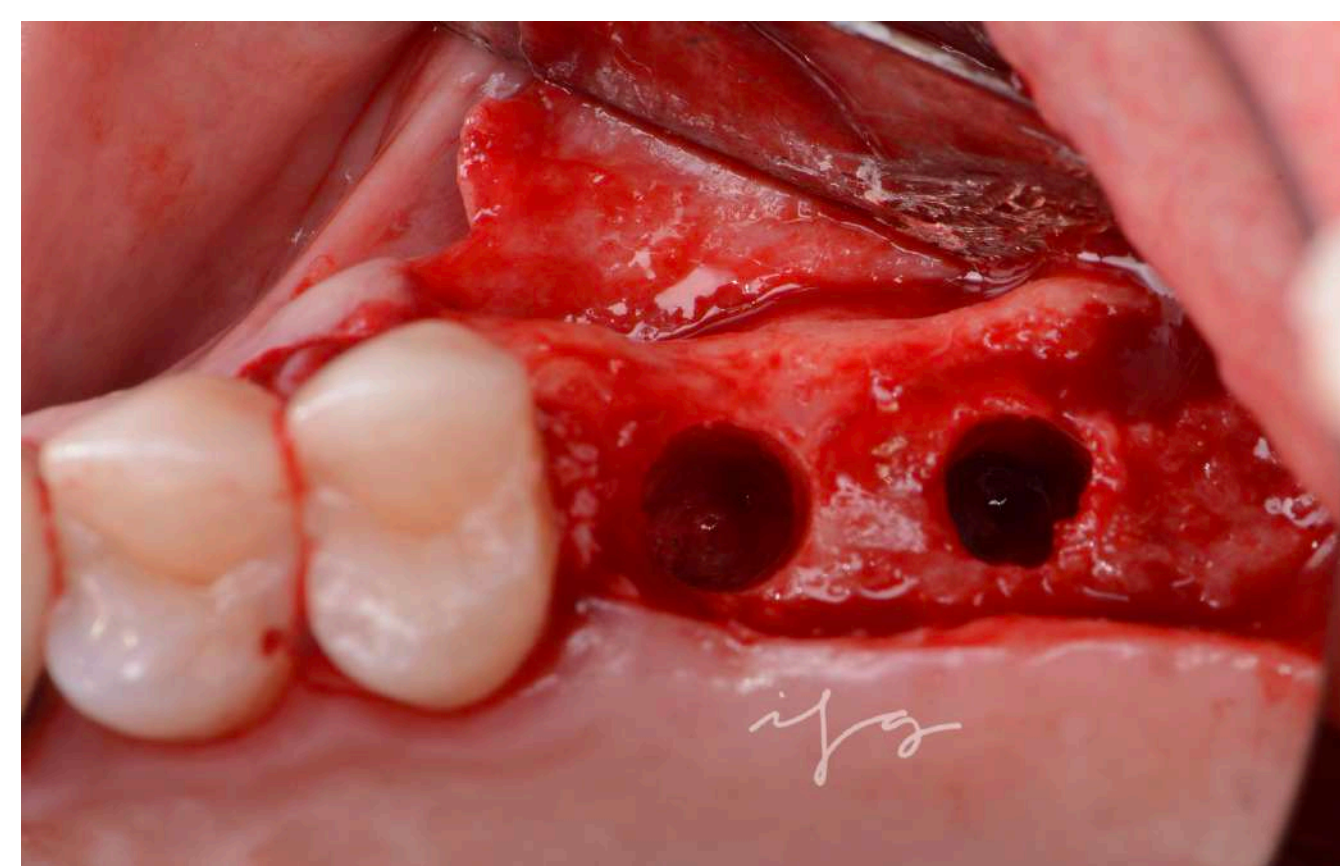


Socket shield technique #1.1

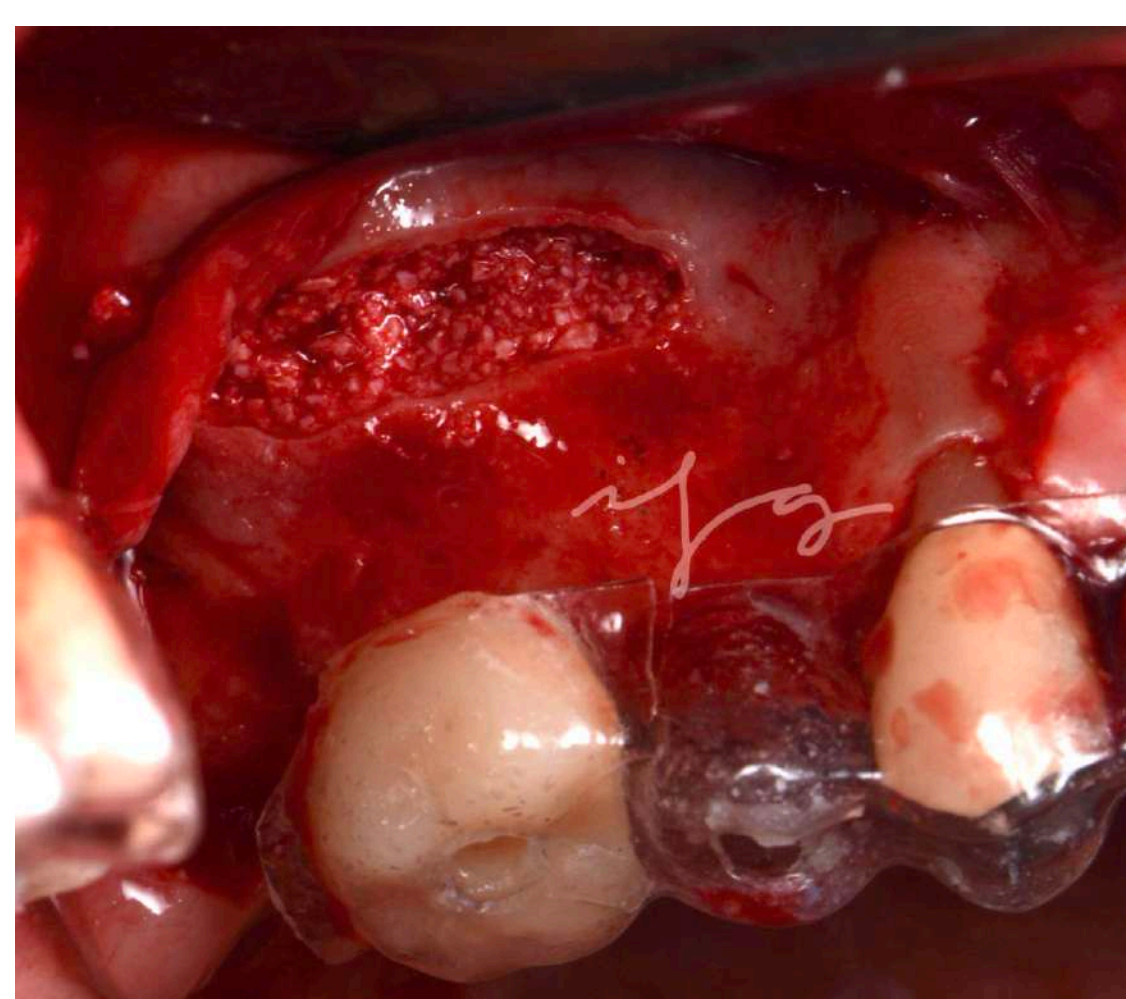
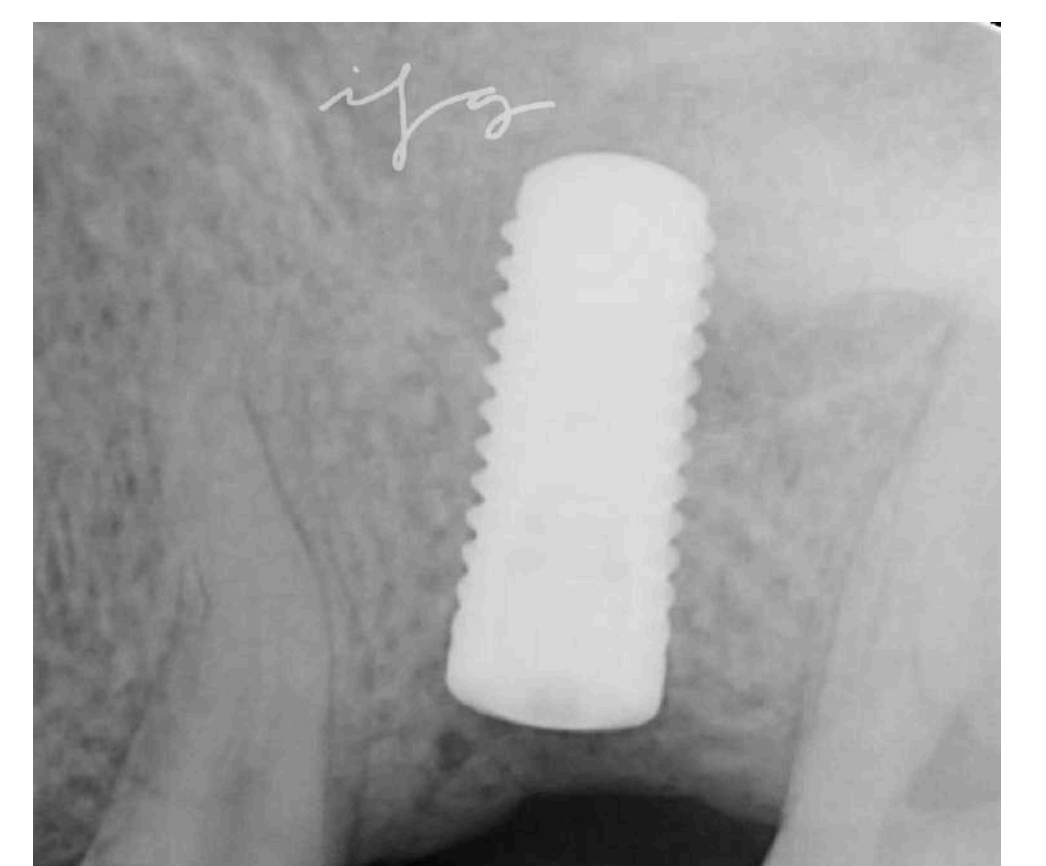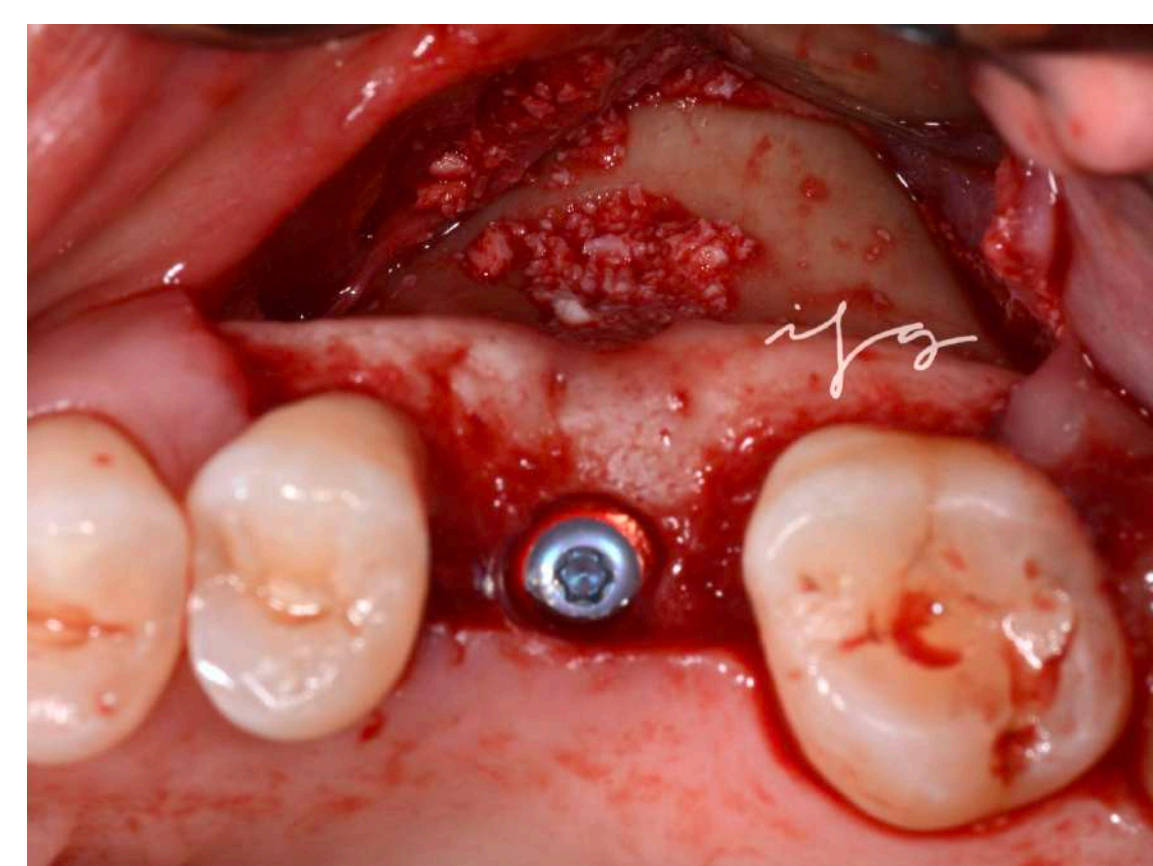
Sinus Augmentation



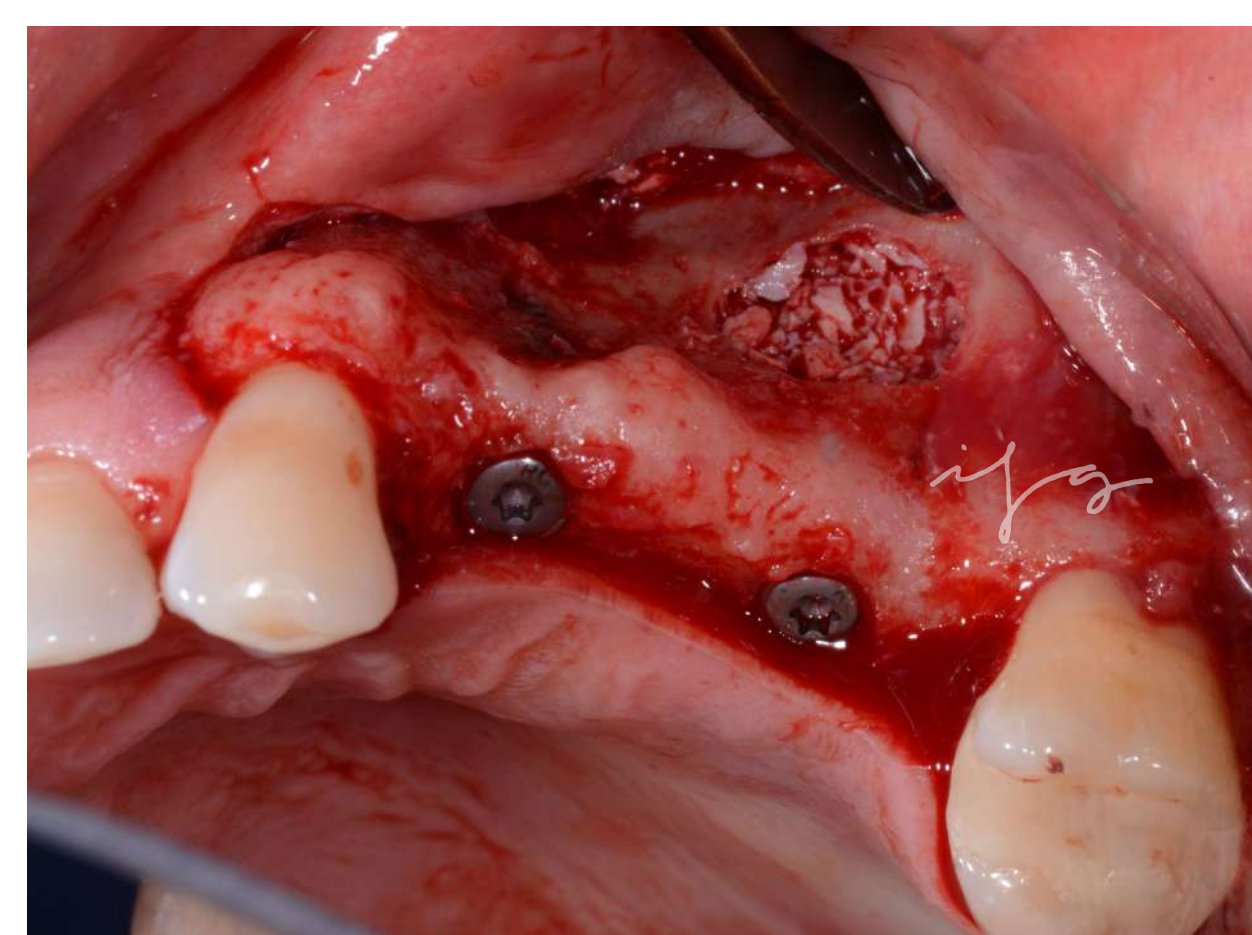
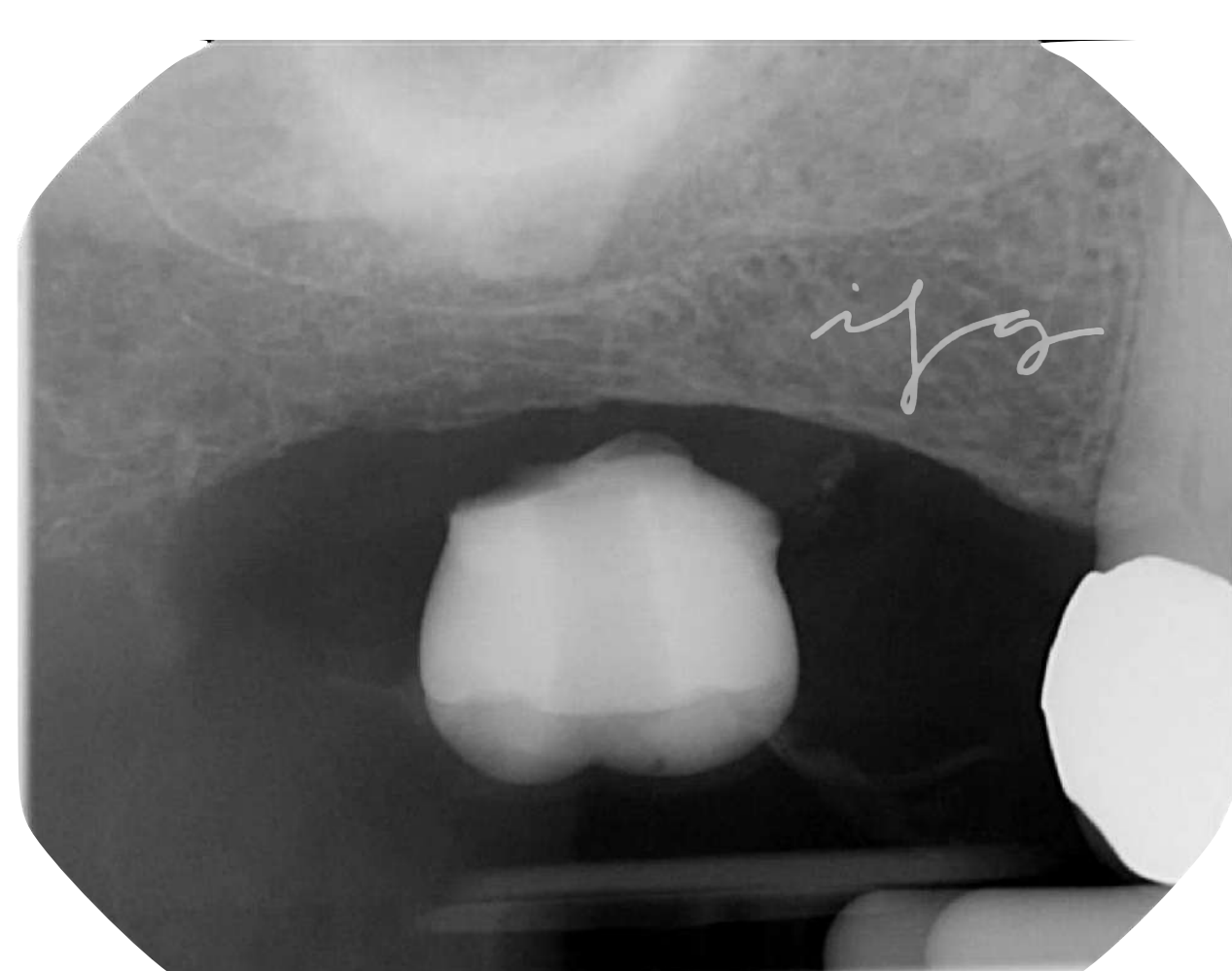Vertical sinus lift with osseodensification burs



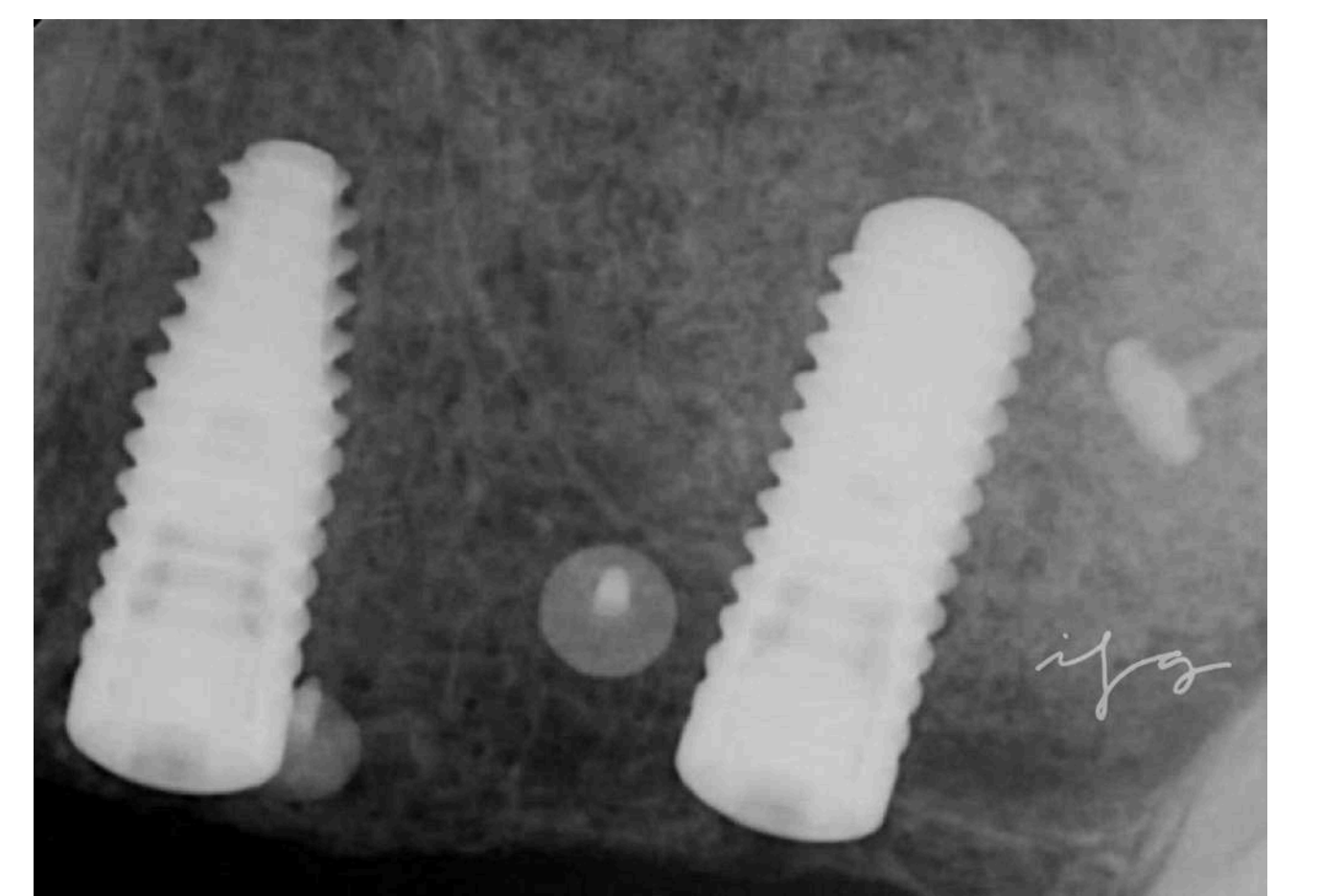
Lateral sinus lift with simultaneous implant placement



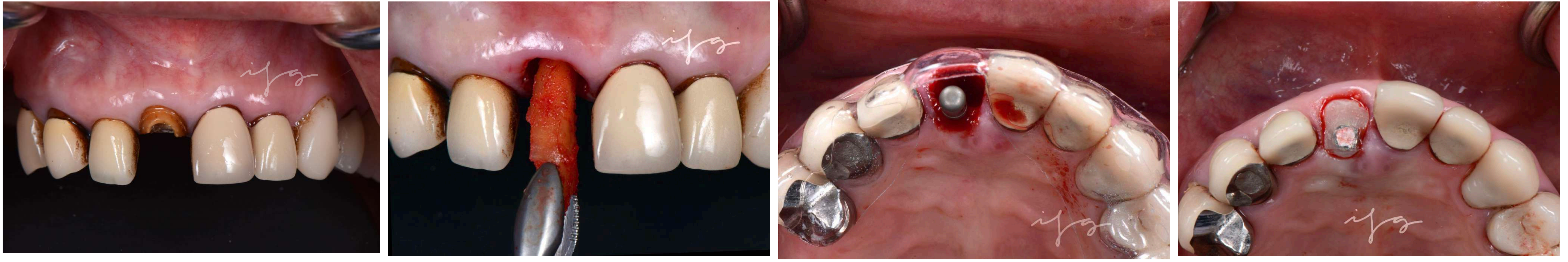Lateral sinus lift with staged implant placement



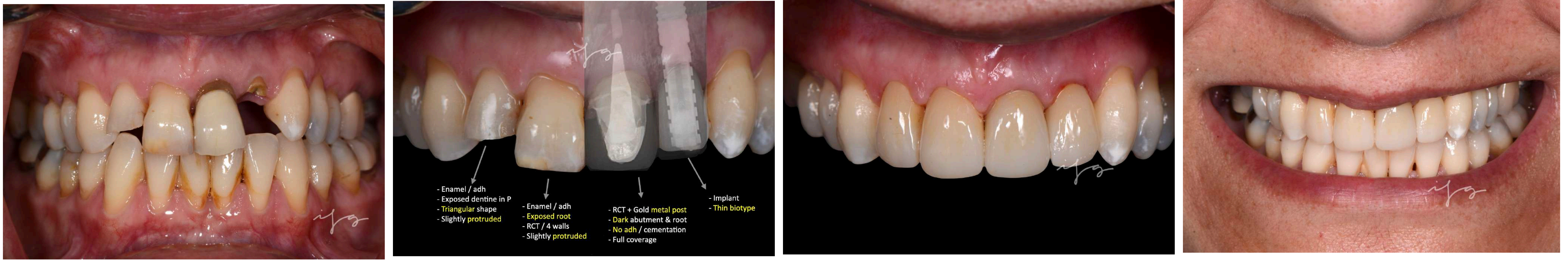
Lateral sinus lift with simultaneous implant placement + GBR



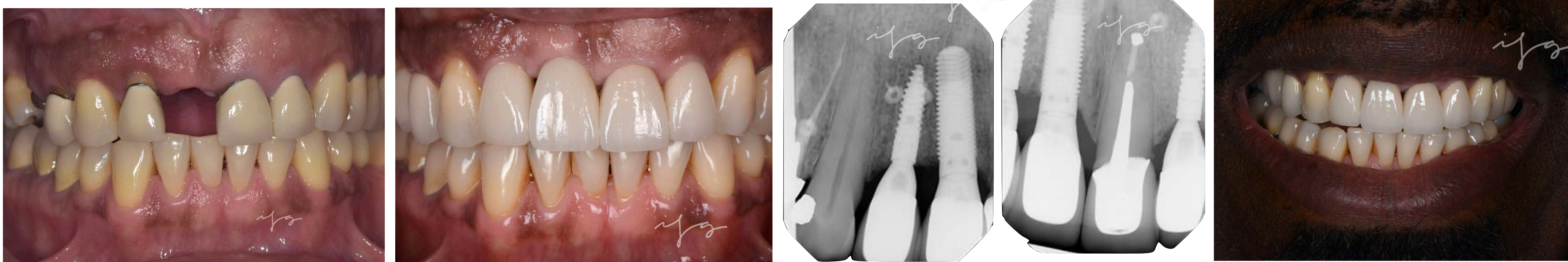
Aesthetic treatment with implants



Immediate implant placement # 1.1 with customized healing abutment

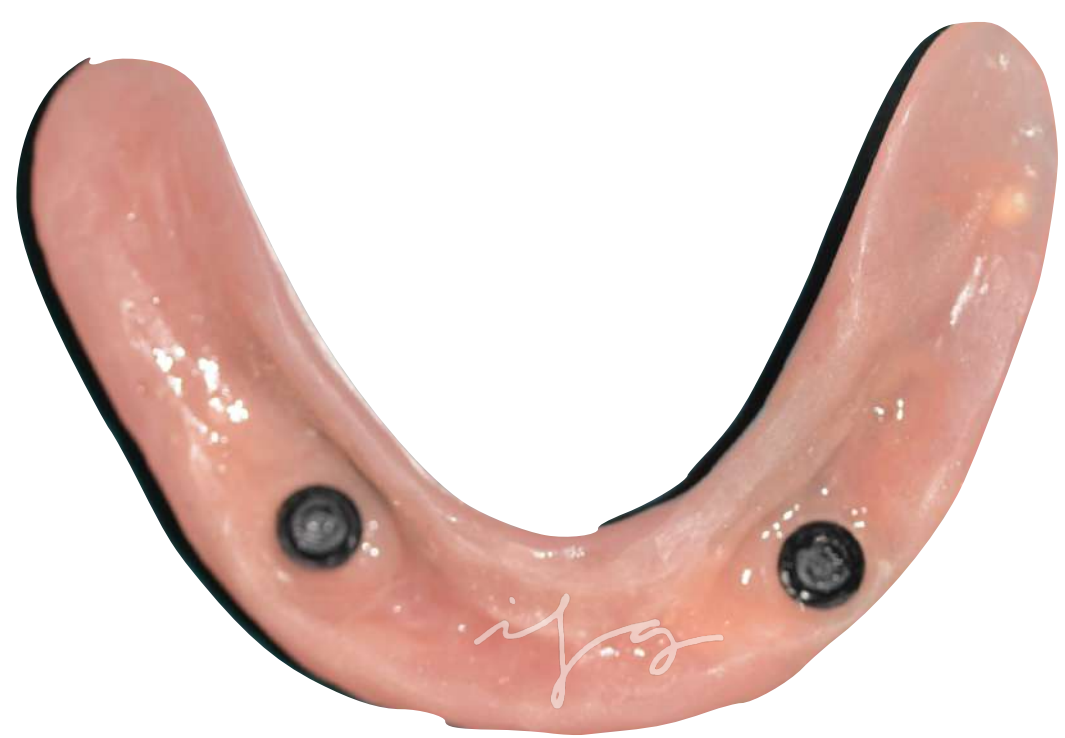

Immediate implant placement #2.1 + zirconia crowns # 1.1, 1.2, 2.1, 2.2 after traumatism

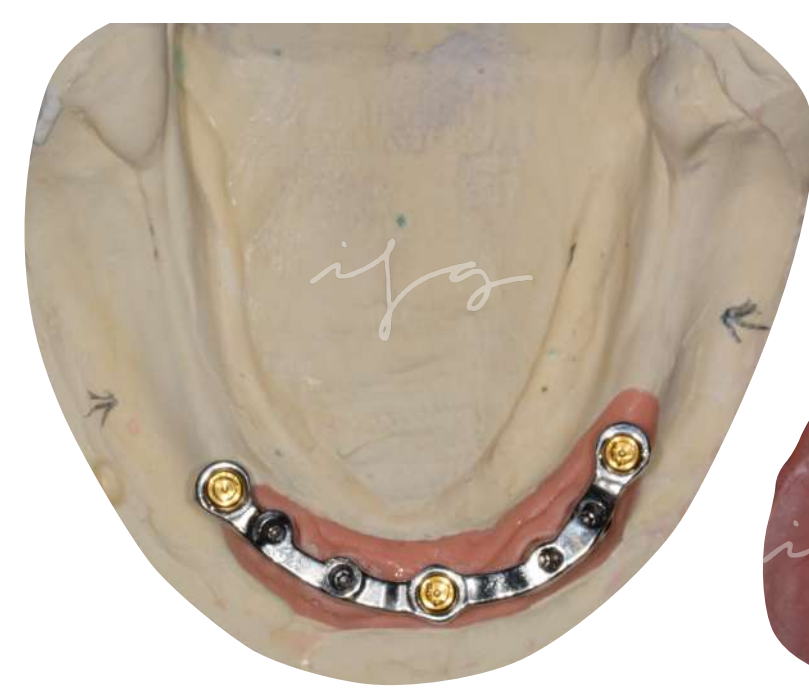

Anterior maxilla reconstruction: preexisting implant #1.1, implant placement #1.4, 1.2, 2.2 + PFM crowns

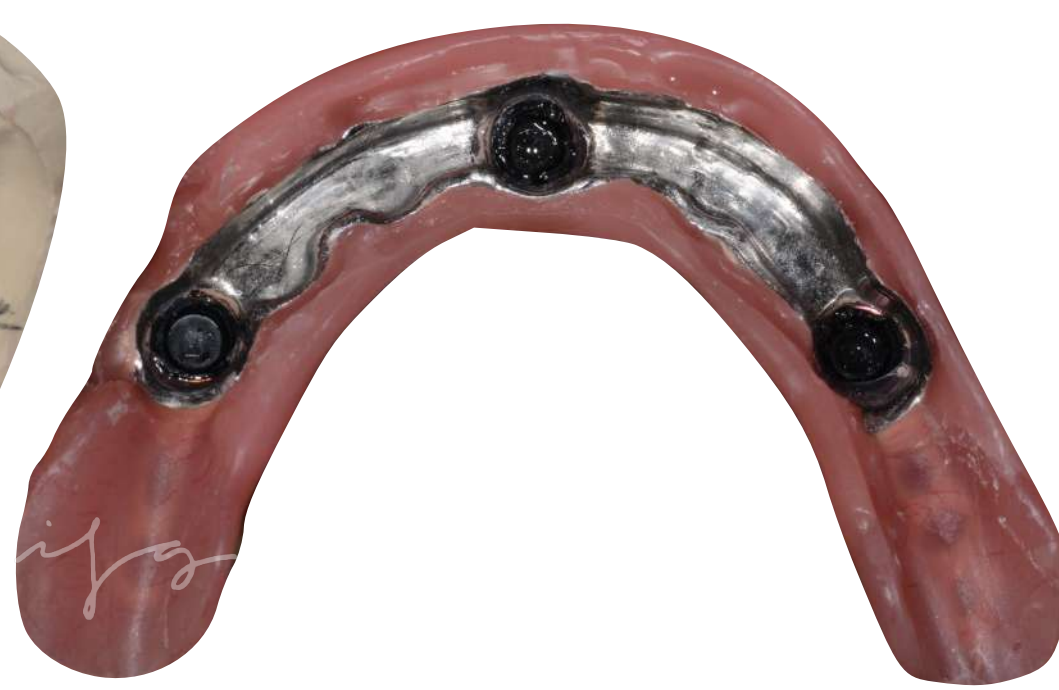More Prosthetic Designs



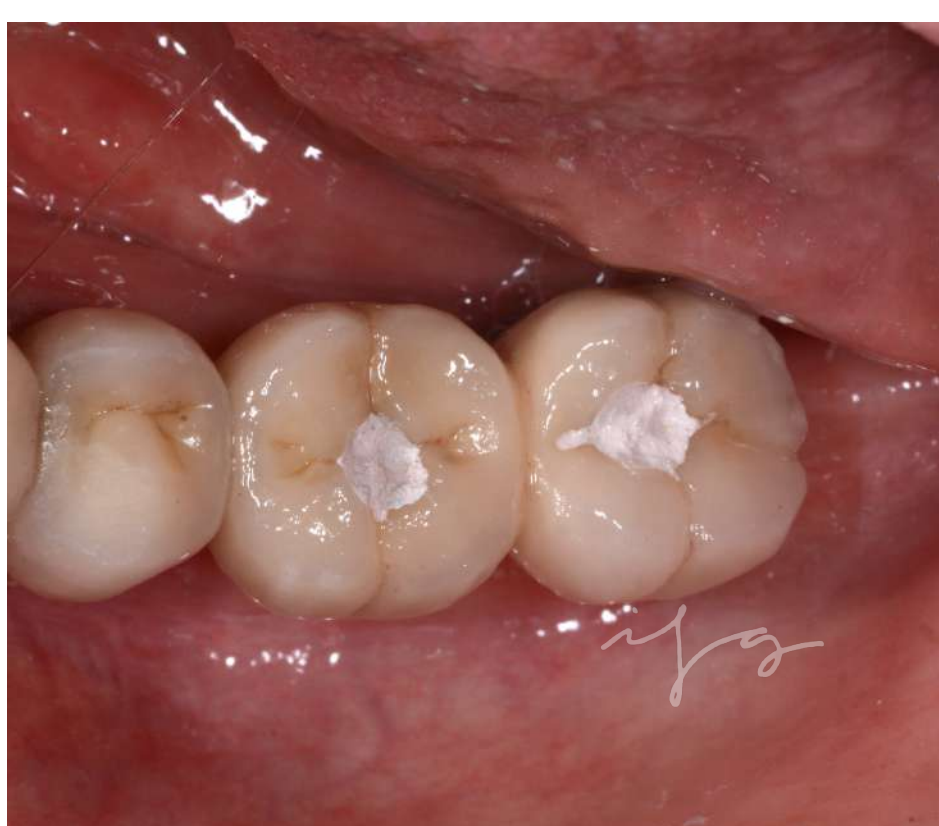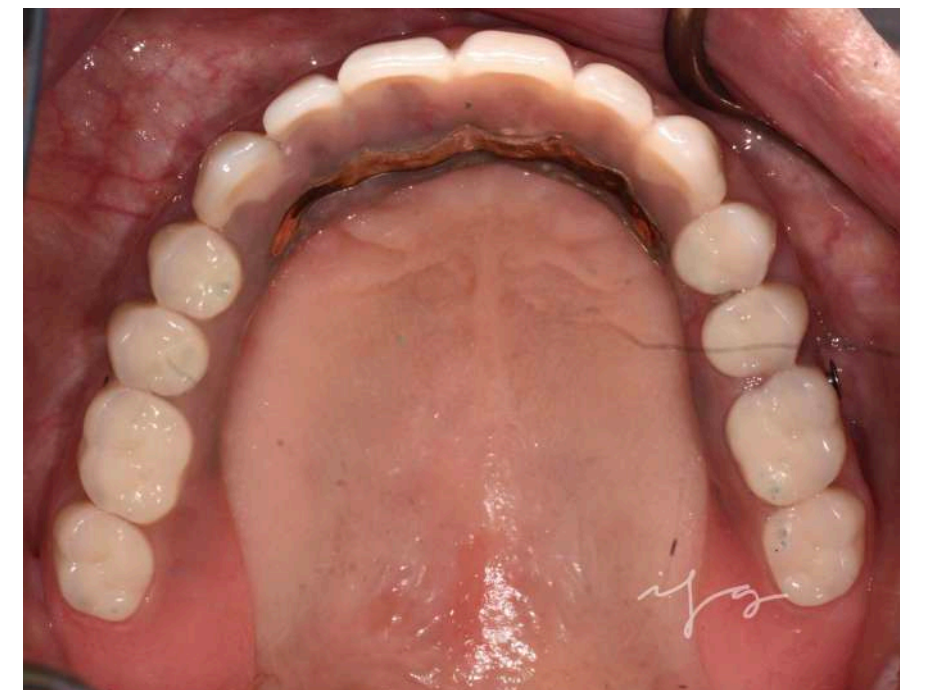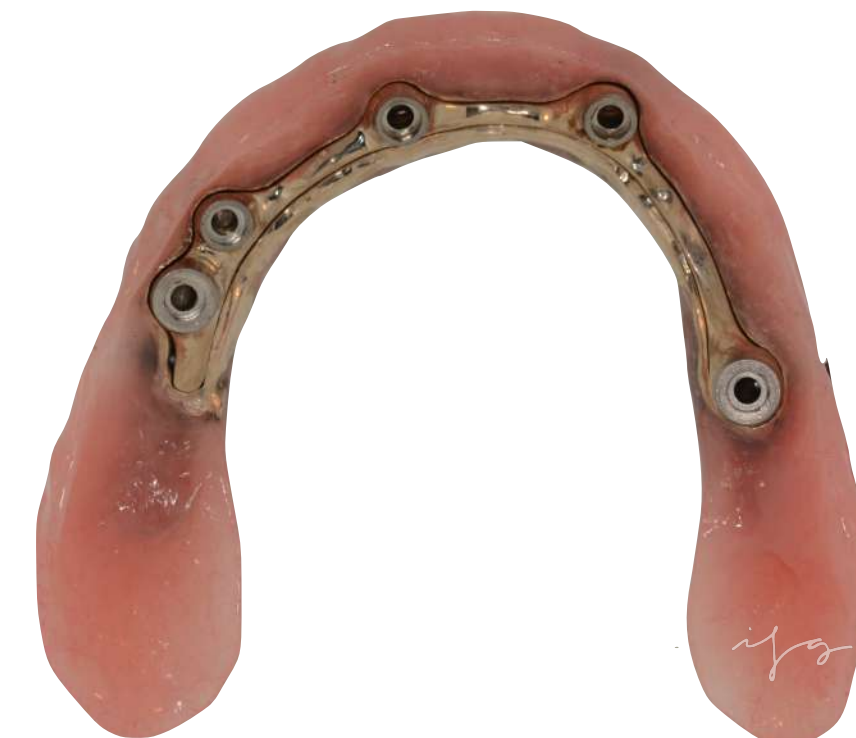OD: Locator abutments



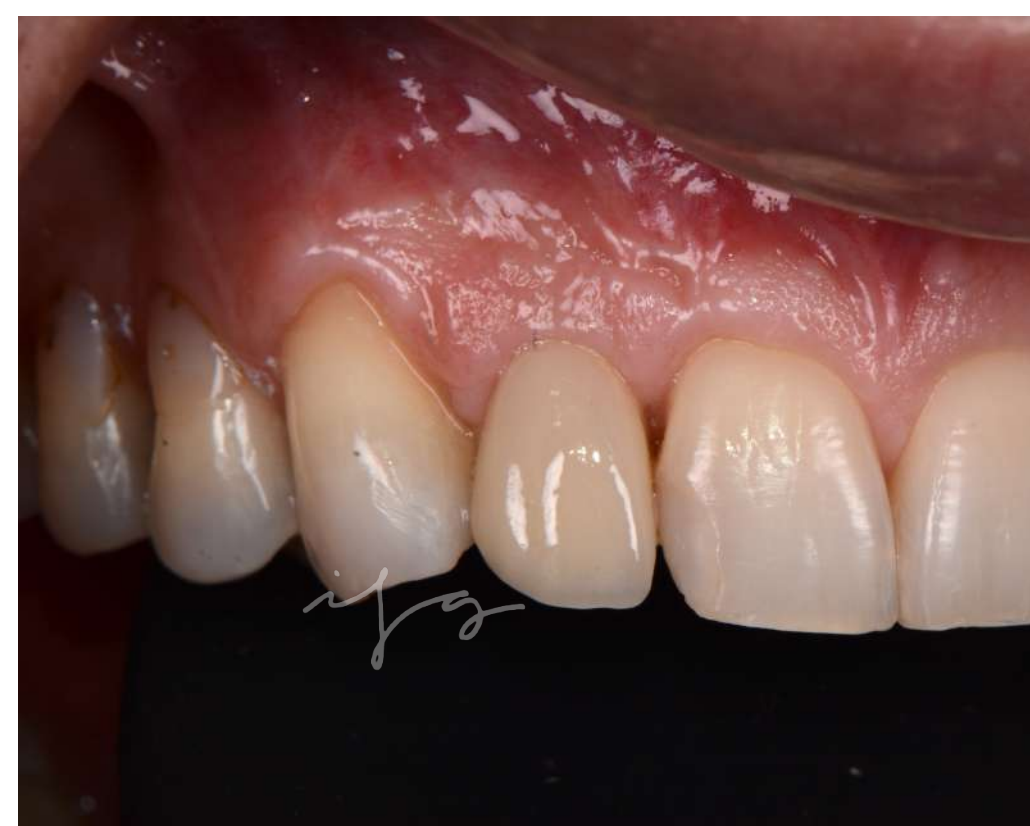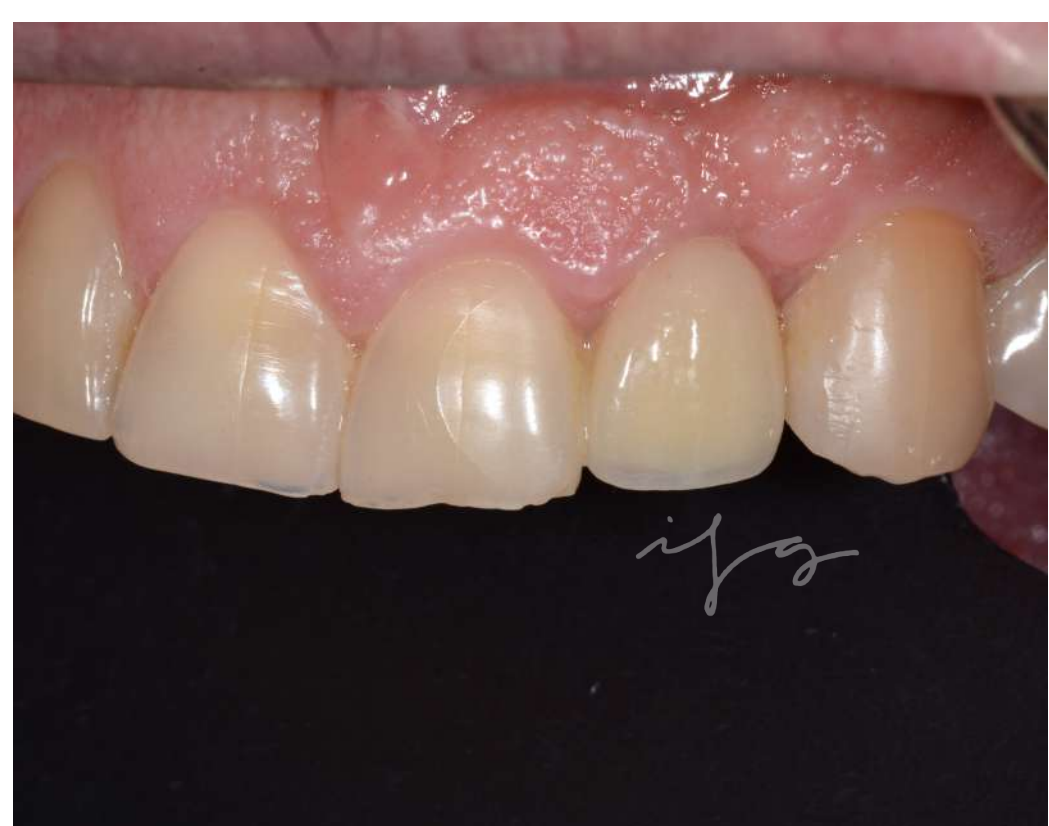OD: Bar + suprastructure + Locator abutments



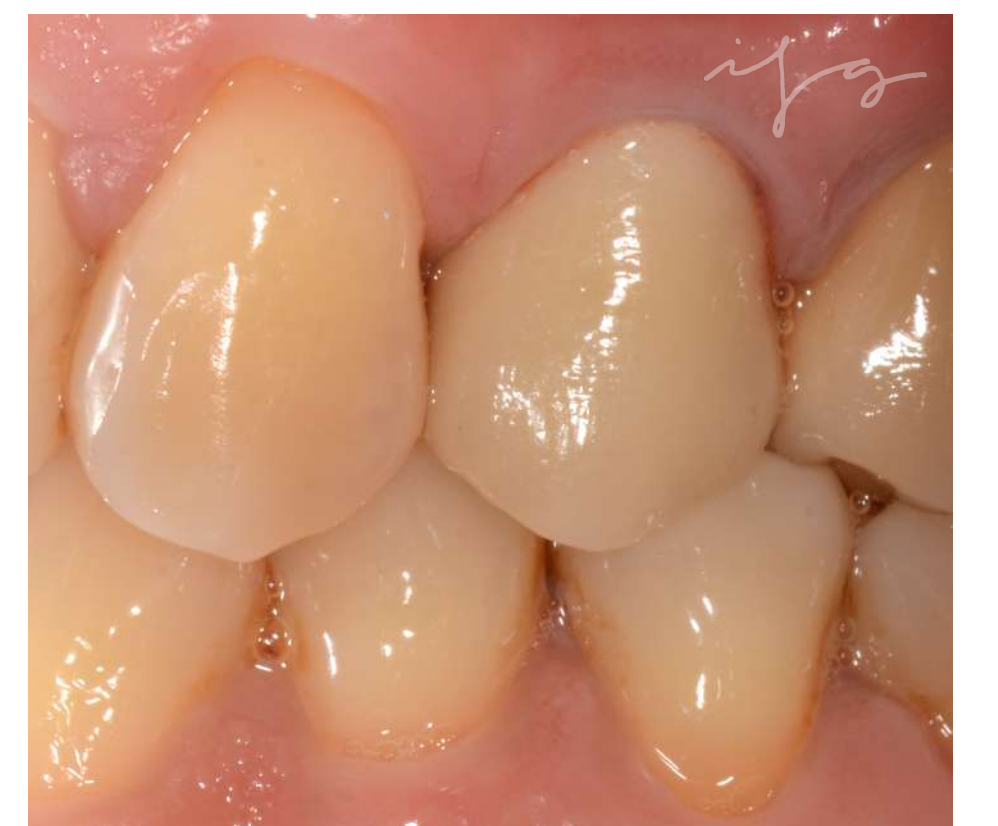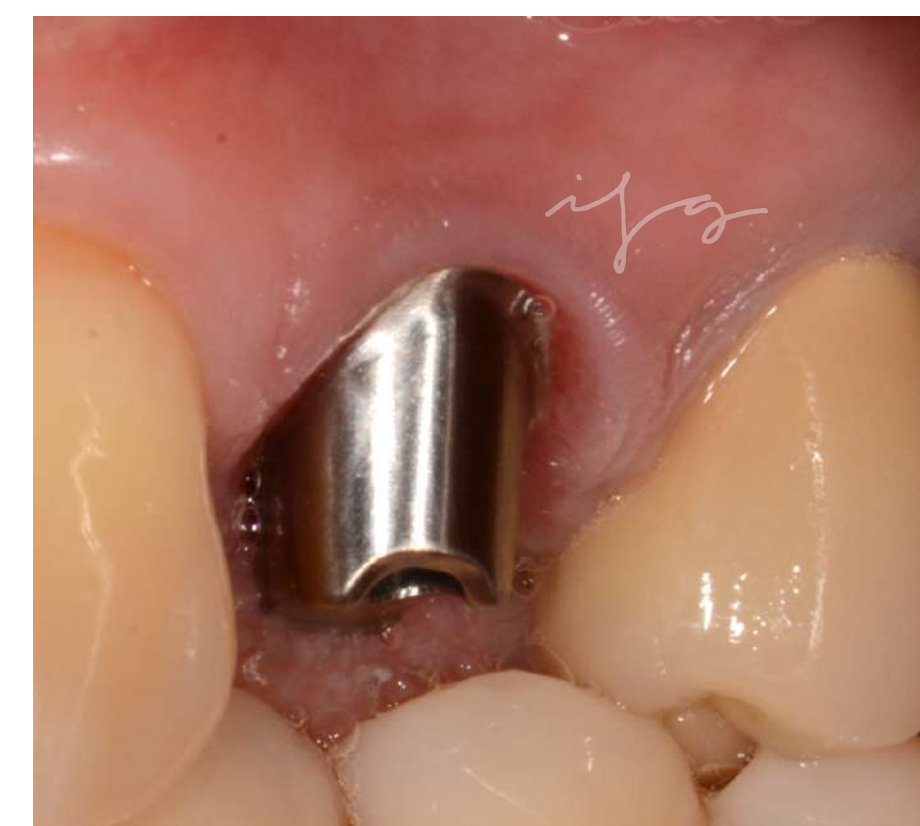OD: Bar + suprastructure + clips



Screw-retained crowns with CAD/CAM custom - designed Cr-Co abutment

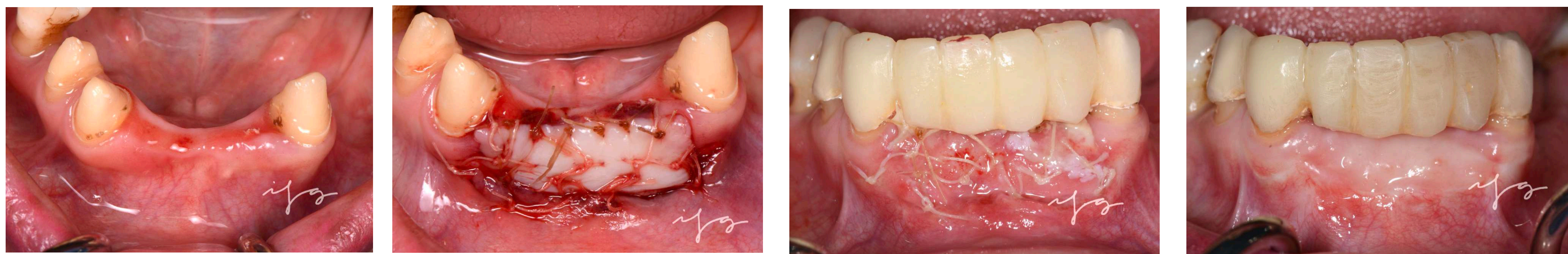

Cemented crown with custom-designed gold abutment

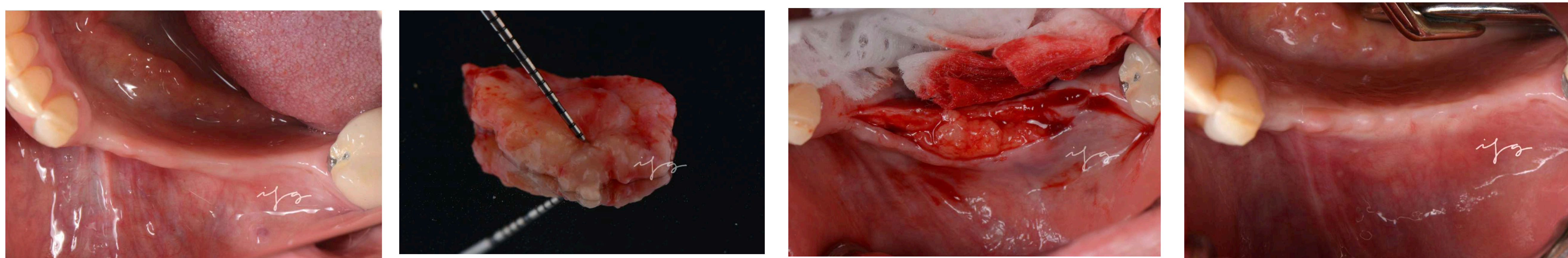


Cemented crown with CAD/CAM custom-designed Cr-Co abutment

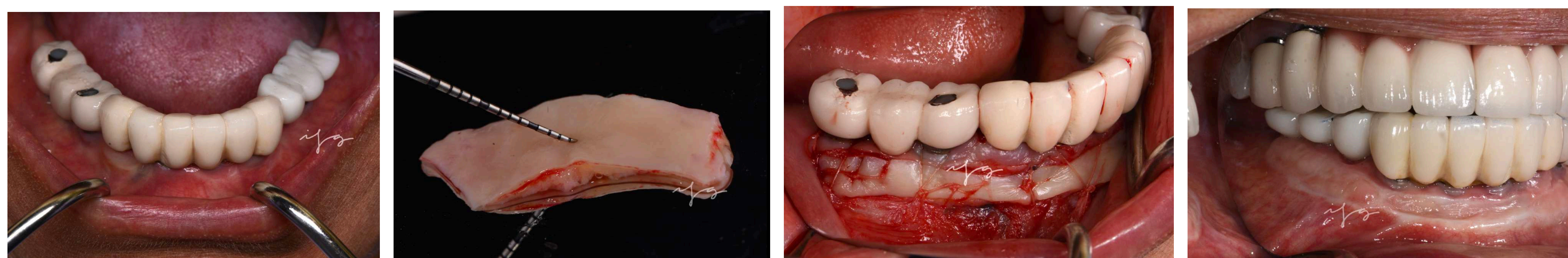
Soft Tissue Management



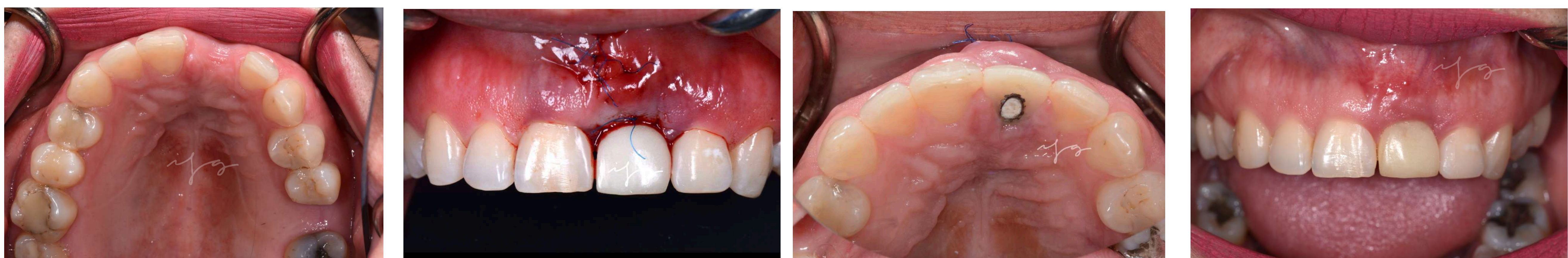FGG to improve soft tissue quality before GBR in anterior mandible



CTG to improve soft tissue thickness before GBR in posterior mandible

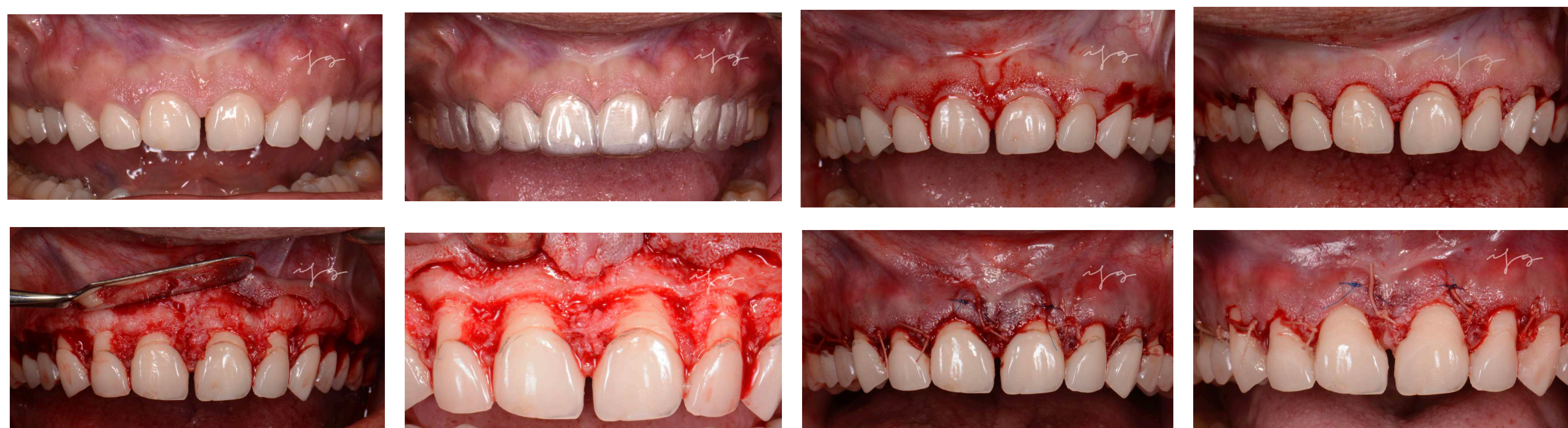


FGG to improve depth of vestibule and keratinized tissue around old full mouth fixed implant restoration



CTG to improve soft tissue contour simultaneously with implant placement in anterior maxilla

Crown lengthening



Aesthetic crown lengthening in altered passive eruption case